

## **TOXICITY EFFECT OF ETHANOLIC *Eucalyptus* LEAVES EXTRACT ON WHITE NORWAY RAT, (*Rattus norvegicus* VAR. *ALBUS*)**

**Mourad, A. A. M.**

**Plant Protection Res. Inst., Agric. Res. Center, Giza, Egypt**

### **ABSTRACT**

The toxic effects of ethanolic camphor leaves extract, *Eucalyptus camaldulensis* was studied on some biochemical aspects and histopathological studies of white Norway rat, *Rattus norvegicus*. Results showed that LD<sub>50</sub> values was 131.56 mg/kg b.w. Oral administration of sub-lethal dose ( $\frac{1}{4}$  LD<sub>50</sub>) of tested extract caused significant decrease for the body weight at 24, 48 and 72 hrs after administration. In contrast, there were significant increase for the internal organs weight (liver, kidney, heart, spleen, lung, and intestine) in all cases. Also, the same dose of extract induced a noticeable dysfunction in AST, ALT enzymes, total protein and prothrombin time profile as they significantly increased in plasma after treatment. Also, the effect of  $\frac{1}{4}$  LD<sub>50</sub> of ethanolic camphor leaves extract for 24, 48 and 72 hours on liver of *R. norvegicus* were studied. The microscopical examination showed that there were injuries in liver tissue at 24, 48 and 72 hrs after administration. Generally, ethanolic camphor leaves extract was toxic to rats and exhibited a higher effect on body weight, internal organs, tested enzyme system and liver tissue of rats.

### **INTRODUCTION**

Pesticide research in the agriculture is generally continuous to emphasize on the development and use of synthetic broadly non-toxic compounds. From accumulated research data, it appears that this goal may be achieved through the use of natural pesticides. Several plant products have shown to possess properties that would make them efficient pest control agents. Therefore, many bioactive compounds, which proved satisfactory in pest control, were isolated, identified and evaluated by researchers, i.e. Singh (1994), Bignell and Dunlop (1996) and El-Gengaihi *et al.* (1997). The present investigation aimed to study the toxicity of ethanolic camphor leaves extract to rats.

### **MATERIALS AND METHODS**

#### **Tested plant:**

The *Eucalyptus* leaves used in this study were collected during summer. One species of camphor had been used, River red gum, *Eucalyptus camaldulensis* (Fam. : Myrtaceae). This species was collected from Giza Governorate (Dokki area). The plants were identified by the Department of Timber-trees Research, Horticultural Research Institute, Agricultural Research Center.

**Plant preparation and extraction:**

Leaves were collected and cleaned from the dust and debris. Leaves of camphor were dried under room temperature of  $28\pm 1^{\circ}\text{C}$  for at least one week. The dry leaves were ground in a grinder to a coarse powder. Extraction was carried out according to the method adopted by Freedman *et al.* (1979) with minor modification (where ground leaves were soaked in the chosen solvent instead of using Soxhlet procedure). Then 150 gm of plant material were extracted with about 750 ml of ethyl alcohol 95%.

**Tested animals:**

Albino Norway rat, *Rattus norvegicus* laboratory strain was used in the present experiments (170 -200 grams body weight). The unhealthy and pregnant animals were excluded. All animals were starved for 12 hours before treatments and allowed free access to water.

**LD<sub>50</sub> determination:**

The test was carried out on individually caged Albino rat, *Rattus norvegicus*. Ten rats were orally administrated containing the tested dosages of 40, 60, 80, 100 and 150 mg/Kg body weight from ethanolic camphor extract. Mortality percentages were recorded and LD<sub>50</sub> values were calculated by the moving-average interpolation method using standard tables and simplified formula given by Horn (1956).

**Biochemical assays:**

Effect of sublethal dose ( $\frac{1}{4}$  LD<sub>50</sub>) of camphor ethanolic extraction on some enzymes activity was studied as physiological response. Animals were orally administrated with  $\frac{1}{4}$  LD<sub>50</sub> of camphor leaves ethanol extract as a single dose. The treated rats were scarified after 24, 48 and 72 hrs post treatment. Blood samples were collected by retro-orbital sinus puncture in trisodium citrate 3.8% as an anticoagulant (1 ml citrate solution /1 ml blood) and then centrifuged at 3000 r.p.m for 15 minutes. Plasma was collected and frozen at  $-20^{\circ}\text{C}$  until used. Aspartate aminotransferase (AST), Alanine aminotransferase (ALT), Total Protein (TP), Prothrombin Time (PT) were determined according to Dacie and Lewis (1984).

**Histopathological studies:**

Animals were divided into groups (each of 5 rats) for the treatment and another one as a control. Then orally intubated with sub-lethal doses  $\frac{1}{4}$  LD<sub>50</sub> of ethanolic camphor leaves extract as a single dose. Animals were decapitated after 24, 48 and 72 hrs post-treatment and pieces of liver was fixed for histopathological examination in 10% formalin. Section at 4  $\mu$  thickness were prepared and stained with hematoxylin and eosin according to the technique of (Banchroft *et al.*, 1996).

## **RESULTS AND DISCUSSION**

**Toxicity of ethanolic camphor leaves extract to *Rattus norvegicus*:**

The mortality percents and LD<sub>50</sub> caused by the tested plant extract, *Eucalyptus camaldulensis* administered to white Norway rat, *Rattus norvegicus* are recorded in Table (1) from which it was found that, no death was observed to any of the tested rats by 40 mg/kg body weight where as

only 10% mortalities were observed within the group given 60 mg/kg body weight. The mortalities percents were increased with increasing the tested doses, then 80, 100 and 150 mg/kg body weight caused 20, 30 and 60% mortalities, respectively. The time of death was decreased by increasing the tested doses. Generally, the average time to death for all tested doses will be 7.10 days. The LD<sub>50</sub> and LD<sub>90</sub> values were tabulated in Table (1), with their corresponding slopes. So, it could be arranged ethanolic camphor extract with LD<sub>50</sub> equal 131.56 mg/kg body weight as moderately toxic compound against rats according to Loomis (1976). From previously mentioned results, it can be proposed that the ethanolic camphor leaves extract can be used as a useful potent rodenticidal baits for controlling rodents.

Accordingly the toxic effect of tested plant extract may be due to the essential oils of leaves of *Eucalyptus* sp. showed that cineole (eucalyptol) content ranged from 13 to 78% of the total oil (Edwards *et al.*, 1993). In the same trend, Wang and Fujimoto (1993) found that the oils from the dried leaves of *Eucalyptus* sp. are potential source of 1,8-cineole (eucalyptol). This essential oils of leaves of *Eucalyptus* sp. when analyzed by GC and GC/MS contain about 60 monoterpenoids, the major components of the oil are 1,8-cineole (74.25%), alpha-pinene (11.6%) and p-cymene (4.5%) (Bignell and Dunlope, 1996).

**Table (1): Toxic effects of ethanol plant extract of camphor against Albino rat, *Rattus norvegicus*.**

Ethanolic camphor leaves extract					
Dose (mg/kg b.w.)	Mortality%	Time to death (day) Mean±SE	LD <sub>50</sub> (mg/kg b.w.)	LD <sub>90</sub> (mg/kg b.w.)	Slope of regression lines
40	0	7.10±0.60	131.56	280.87	3.89±0.50
60	10				
80	20				
100	30				
150	60				

**Effect of ethanolic camphor leaves extract on weight of body and different organs of *Rattus norvegicus*:**

Table (2) revealed that the body weight of animals treated with ¼ LD<sub>50</sub> of camphor leaves ethanol extract was significantly decreased than untreated ones (175.30, 173.40 and 170.90 g) at 24, 48 and 72 hours post-treatment compared to untreated animals (190.0 g). The losses in body weight of rats after administration ¼ LD<sub>50</sub> of camphor leaves extract may be due to the loss of appetite. In contrast, a significant increase occurred in the weight of liver, kidney, heart, spleen, lung and intestine following camphor leaves ethanol extract treatment at 24, 48 and 72 hrs post-treatment. The same observation was noticed by El-Deeb *et al.* (2008).

**Biochemical response:**

Aspartate aminotransferase (AST) and Alanine aminotransferase (ALT) are important and critical in biological processes. They have role in amino acid metabolism and biosynthesis and are considered as specific

indicators of liver damage. Measuring the Prothrombin Time (PT) provides a satisfactory method to evaluate the efficacy of rodenticide (Hadler and Shadbolt, 1975).

Data shown in Table (3) indicate the effect of sublethal dose ( $\frac{1}{4}$  LD<sub>50</sub>) of camphor leaves extracted by ethanol on AST, ALT enzymes, Total Protein (TP) and PT in blood plasma. Results showed that AST level increased with significant with the prolongation of post-treatment period as its values were 10.75, 11.80 and 13.85 U/L at 24, 48 and 72 hours after treatment, respectively when compared with control 7.90 U/L.

**Table (2): Effect of  $\frac{1}{4}$  LD<sub>50</sub> of camphor leaves ethanolic extract on the different organs weight of Albino rat, *Rattus norvegicus*.**

Parameters (g)	Untreated Mean±SE	Hours post-treatment		
		24 Mean±SE	48 Mean±SE	72 Mean±SE
Body weight	190.0±1.22	**175.30±3.60	**173.40±1.40	**170.90±2.54
Liver	4.30±0.06	**8.90±0.28	**9.10±0.08	**9.20±0.16
Kidney	1.80±0.03	*2.68±1.05	*2.80±0.17	**2.96±0.23
Heart	1.00±0.02	*1.32±0.92	*1.46±0.01	*1.90±0.15
Spleen	0.32±0.05	*0.79±0.11	*0.91±0.25	**1.12±0.33
Lung	1.20±0.50	*1.95±0.95	*2.11±0.01	**2.35±0.50
Intestine	13.11±1.25	*16.35±2.0	**17.22±1.55	**17.65±0.06

\* Significant (P<0.05)

\*\*Highly Significant (P<0.01)

Also, ALT activity increased significantly from 9.10, U/L in control to 11.55, 13.75 and 14.90 U/L at 24, 48 and 72 hours post-treatment, respectively. Regarding total protein, it is cleared that camphor leaves extract treatment increased significant in total protein in plasma and its values 8.90, 9.85 and 10.50 g/dl at 24, 48 and 72 hours post-treatment, respectively comparing with 6.50 g/dl in control. At the same time, the effect of ethanolic camphor leaves extract on prothrombin time (PT) showed a significant increase all over the tested periods where 26.20, 39.40 and 50.80 seconds at 24, 48 and 72 hours post-treatment, respectively. Normally, plasma AST and ALT are low but after extensive tissue damage these enzymes are liberated into the blood (Kachmor, 1970). And, the amount of AST is directly proportional to the number of cells damaged and the interval of time between tissue injury and AST determination (Tilkian *et al.*, 1983).

From previously mentioned results, it could be proposed that the increase in plasma enzyme level may be attributed to increase of cell membrane permeability. The present results are in accordance with Shashi-Gupta *et al.* (1998). The lengthened (PT) from a toxic dose of coumarins or indandiones may be evident within 24 hrs, but usually reaches a maximum in 36-72 hrs (Smolinske *et al.*, 1989). Lengthened (PT) occurs in response to doses much lower than that necessary to cause hemorrhage (Mack, 1994).

**Histopathological effects:**

Histopathological changes in liver tissue of Albino rats, *Rattus norvegicus* after 24, 48 and 72 hrs post-treatment with  $\frac{1}{4}$  LD<sub>50</sub> of ethanolic camphor extract comparing with untreated animals were shown and illustrated in Figs (1-4).

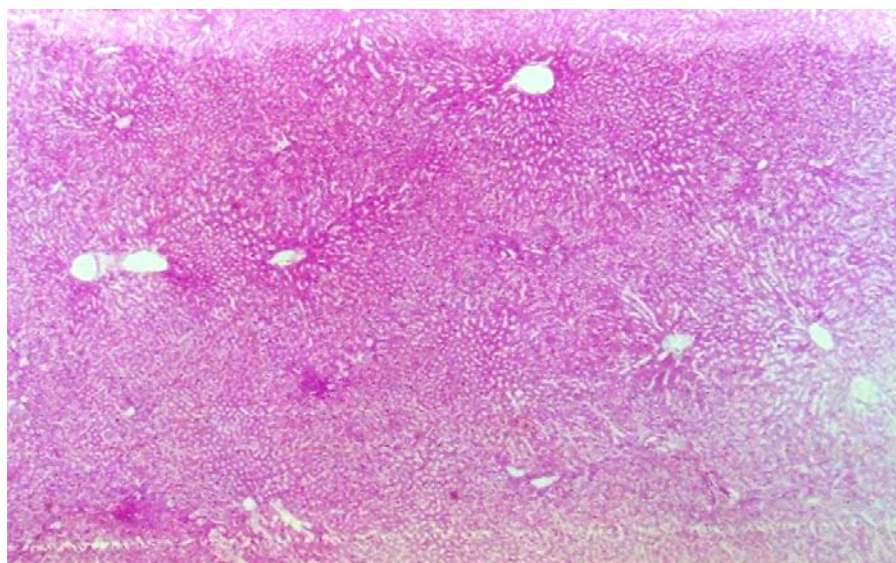
Liver of untreated rats (Fig. 1) showed no histopathological changes and the normal histological structure of the hepatocytes in the hepatic cords, central veins, sinusoids and the portal area having the portal veins, hepatic artery and bile duct. Histopathological changes in liver tissue after 24 hrs post-treatment are shown in Fig. (2) and revealed that the focal mononuclear leucocytes inflammatory cells infiltration in between the degenerated hepatocytes. While, after 48 hrs post-treatment Fig. (3) revealed that the mononuclear leucocytes inflammatory cells infiltration in the periportal tissue of the bile duct in the portal area. Also, Fig. (4) indicated that, there was mononuclear leucocytes inflammatory cells infiltration in the portal area surrounding the bile duct when observed 72 hrs post-treatment. These findings are in agreement with Mahran (1990) and El-Deeb *et al.* (2003)

**Table (3): Effect of ¼ LD<sub>50</sub> of camphor leaves ethanolic extract on biochemical findings of Albino rat, *Rattus norvegicus*.**

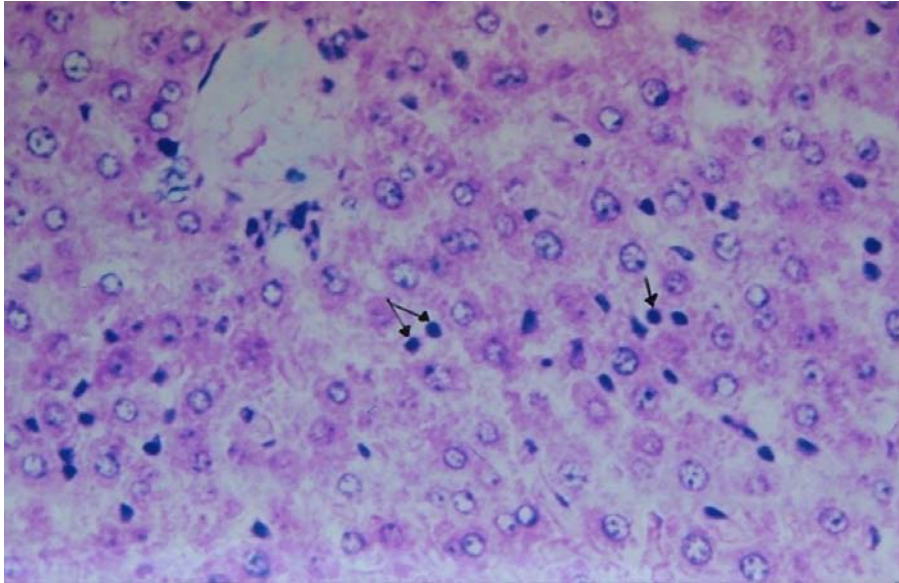
Parameters	Untreated Mean±SE	Hours post-treatment					
		24		48		72	
		Mean±SE	Diff.%	Mean±SE	Diff.%	Mean±SE	Diff.%
AST (U/L)	7.90±1.20	10.75±0.16	36.08	*11.80±1.42	49.37	**13.85±0.20	75.32
ALT (U/L)	8.70±1.22	11.55±2.28	32.76	*13.75±0.28	58.05	**14.90±0.34	71.26
TP(g/dL)	6.50±2.21	*8.90±1.16	36.92	*9.85±2.43	51.54	*10.50±0.33	61.54
PT(second)	10.60±1.05	26.20±2.08	147.17	**39.40±1.11	271.70	**50.80±0.57	379.25

\* Significant (P<0.05)

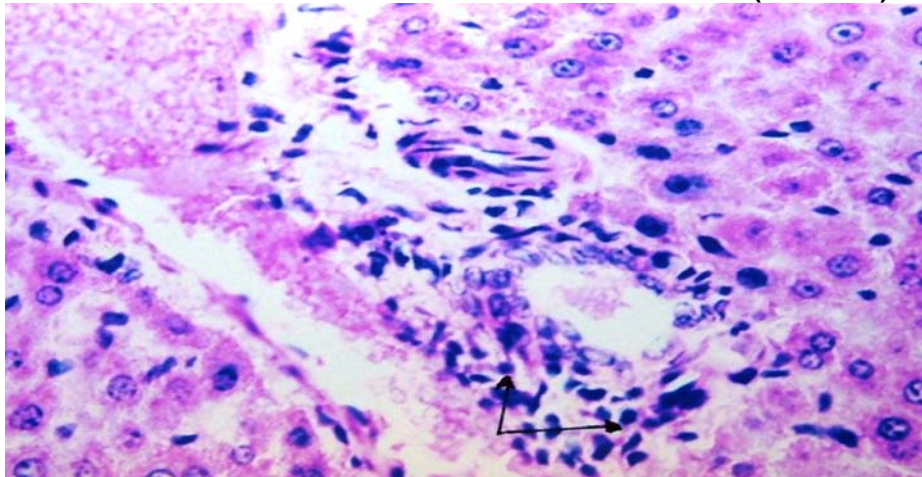
\*\*Highly Significant (P<0.01)



**Fig. (1): Liver tissue of untreated albino rat (control) showing the normal histological structure of the control vein, hepatocytes in the hepatic cords and the portal area.**

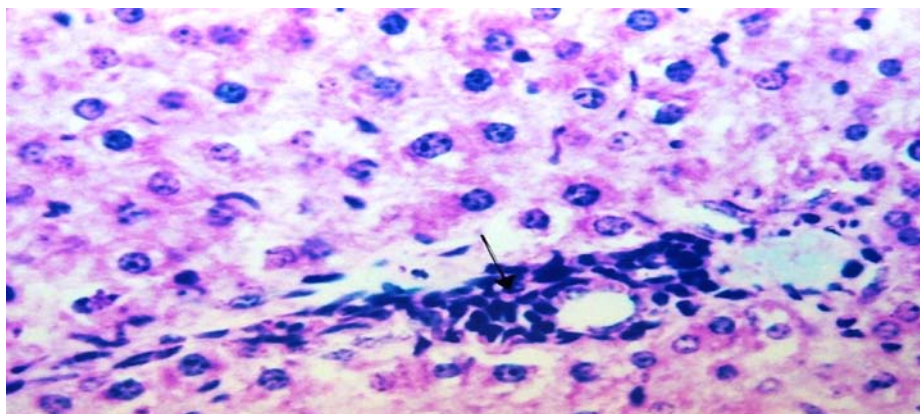


**Fig. (2):** Liver tissue of rat 24 hrs after administrated  $\frac{1}{4}$  LD<sub>50</sub> of camphor extract, showing focal mononuclear leucocytes inflammatory cells infiltration between the degenerated hepatocytes.  
(H&EX160)



**Fig. (3):** Liver tissue of rat 48 hrs after administrated  $\frac{1}{4}$  LD<sub>50</sub> of camphor extract, showing mononuclear leucocytes inflammatory cells infiltration in the periductal tissue of the bile duct in the portal area.  
(H&EX160)





**Fig. (4): Liver tissue of rat 72 hrs after administrated  $\frac{1}{4}$  LD<sub>50</sub> of camphor extract, showing mononuclear leucocytes inflammatory cells infiltration in the portal area surrounding the bile duct. (H&EX160)**

### REFERENCES

- Banchroft, J. D.; A. Stevens and D. R. Turner (1996): Theory and practice of histological techniques. 4<sup>th</sup> ed. Churchill Livingstone, New York, P. 118.
- Bignell, C. M. and P. J. Dunlop (1996): Volatile leaf oils of some South Western and Southern Australian species of the genus *Eucalyptus*. Part VII. Subgenus *Symphyomyrtus* section. *Excertaria Flaver and Fragrance J.*, 11: 35-41.
- Dacie, J. V. and S. M. Lewis (1984): Practical Haematology. (6<sup>th</sup> Ed.) Churchill Livingstone Edinburgh London, Melbourne and New York.
- Edwards, P. B.; W. J. Wanjura and W. V. Brown (1993): Selective herbivore by Christmas beetles in response to intraspecific variation in *Eucalyptus terpenoids*. *Oecologia*, 4: 551-557.
- El-Deeb, H. I.; M. R. Abd-ElKader; W. M. Gabr and H. A. Ahmed (2008): Rodenticidal efficiency of certain compounds against *Rattus norvegicus* and *Rattus rattus alexandrines*. *Egypt. J. Agric. Res.*, 86 (2): 459-469.
- El-Deeb, H. I.; W. M. Gabr; Khidr Fatma K. and E. A. El-Essely (2003): The histopathological effects of warfarin and chlorophacinone anticoagulant rodenticides on male albino rats. *J. Agric. Sci. Mansoura Univ.*, 28 (7): 5685-5698.
- El-Gengaihi, S. E.; N. Z. Dimetry and S. M. Mohamed (1997): Chemical and biological investigation of harmal plant. Alkaloidal investigation. *J. Appl. Entomol.*, 121 (3): 165-167.
- Freedman, B.; L. J. Nowak; W. F. Ewolek; E. C. Berry and W. D. Guthric (1979): A bioassay for plant-derived pest control agents using the European corn borer. *J. Econ. Entomol.*, 72 (4): 541-545.
- Hadller, M. R. and R. S. Shadbolt (1975): Nova1 4-hydroxy coumarin anticoagulant active against resistant rats. *Nature*, 253: 275-277.

**Mourad, A. A. M.**

- Horn, H. J. (1956): Simplified LD<sub>50</sub> (or ED<sub>50</sub>) calculations. Biometreics 12: 311-322.
- Kachmor, J. E. (1970): Enzymes In: Fundamental of clinical chemistry. Ed. By Tietz, N. W., 362-473.
- Loomis, T. A. (1976): Essentials of toxicology. 2<sup>nd</sup> ed.; Lea of Febiger Philadelphia.
- Mack, R. B. (1994): Not all rats have four legs: Superwarfarin poisoning. N. C. Med. J. 55: 554-556.
- Mahran, H. N. (1990): Histological and histochemical studies on the effects of the rodenticide brodifacoum on the liver and small intestine of the white rat. M. Sc. Fac. Science, Menofia Univ.
- Shashi-Gupta, P. K. G.; Meena-Kataria, R. S.; A. Shakoor and V. K. Vijjan (1998): Toxicity of azadirachtin (neem) based formulation in rats. Indian Environ. And Toxicol., 8: 2, 77-80.
- Singh, A. K. (1994): Chemical composition of the leaf oil of *Eucalyptus rediata* Sieb. Ex DC subsp *Rodertsonii* (Blakely) L. J. Essential Oil Res., 6 (6): 657-659.
- Smolinske, S. C.; D. L. Scherger and P. S. Kearns (1989): Supperwarfarin poisoning in children : A prospective study. Pediatrics, 84: 490-494.
- Tilkian, S. M.; M. Conover and A. G. Tilkian (1983): Clinical implications of laboratory tests. The CV Mosby Company, Louis, Toronto, London.
- Wang, H. and Y. Fujimoto (1993): Triterpene esters from *Eucalyptus tereticornis*. Phytochemistry, 33 (1): 151-153.

### تأثير سمية مستخلص أوراق الكافور الإيثانولي علي الفأر النرويجي الأبيض عبد الرؤف أحمد محمد مراد معهد بحوث وقاية النباتات – مركز البحوث الزراعية – جيزة - مصر

تم دراسة تأثير مستخلص أوراق الكافور الإيثانولي علي بعض النظم البيوكيميائية والهستوباثولوجية علي الفأر النرويجي الأبيض.

أوضحت النتائج أن التركيز النصفى المميت LD<sub>50</sub> كانت 131,56 مجم/كجم من وزن الجسم. المعاملة عن طريق الفم للمستخلص المختبر ¼ الجرعة النصف مميتة أحدثت إنخفاض معنوي في وزن الجسم بعد 24، 48، 72 ساعة من المعاملة. بينما كان هناك زيادة معنوية في وزن الأعضاء الداخلية (الكبد والكليّة والقلب والطحال والرئة والأمعاء) في جميع الحالات. أيضا أحدثت نفس الجرعة للمستخلص خلل واضح في وظائف إنزيمات ALT, AST والبروتين الكلي (TP) وزمن البروثرومبين (PT) حيث ارتفعت قيمهم إرتفاعاً معنوياً في البلازما بعد المعاملة. وأيضاً تم دراسة تأثير ¼ الجرعة النصف مميتة من مستخلص أوراق الكافور الإيثانولي عن طريق الفم لمدة 24، 48، 72 ساعة علي كبد الفأر النرويجي الأبيض.

وأظهرت الدراسة من خلال الفحص الميكروسكوبي أن تأثير المعاملة بهذا المستخلص أحدثت ضرراً واضحاً علي أنسجة كبد الفأر النرويجي الأبيض في جميع الحالات المختبرة.

قام بتحكيم البحث

كلية الزراعة – جامعة المنصورة  
مركز البحوث الزراعية

أ.د / فؤاد عبدالحق حسام الدين شاهين  
أ.د / حسن ابراهيم الديب