

**COMPARATIVE STUDIES BETWEEN THE EFFECT OF
CYCLOSPORINE A AND VITAMIN E ON THE KIDNEY OF
ADULT MALE ALBINO RAT
(HISTOLOGICAL AND HISTOCHEMICAL STUDIES)**

Wassef A. Abdallah* and Samia M. Sakr**

*Dep. of Zoology, Faculty of Science, Al-Azhar University

**Biological Sciences Department- Faculty of Education- Ain-Shams University.

ABSTRACT

Cyclosporine A is an immunosuppressive drug used in treatment of autoimmune diseases and for tissue rejection after organ transplantation. This work was carried out to detect the renal lesions induced by cyclosporine A and the role of vitamin E against these effects. Twenty adult male albino rats (*Rattus rattus*) were used. They were divided into four groups (five animals each). Group I: control rats which received daily equivalent amounts of olive oil orally for four weeks. Group II: included rats which were given oral daily doses of vitamin E (400 mg/kg body weight) for four weeks. Group III: in which the rats received daily oral doses of cyclosporine A (10 mg/kg body weight) for four weeks. Group IV: the animals were given both cyclosporine A and vitamin E concomitantly in doses and duration as mentioned before in groups II and III. Examination of kidney of rats which received cyclosporine A only showed patchy areas of histopathological changes. Most of the glomeruli were hypertrophied, others appeared atrophied. Dilatation of both proximal and distal convoluted tubules was also noticed. Mononuclear cellular infiltration was seen in between the renal tubules. Acidophilic hyaline casts were detected in the dilated collecting tubules. Reduction in the PAS positive reaction on the brush borders of the P.C.T. cells was observed. Increase in the thickness of the tubular and glomerular basement membranes was detected. The cytoplasm of the P.C.T. cells showed reduction in its mitochondrial content as well as in acid phosphatase reaction. There was an increase in the collagenous fibres in the glomeruli and around the renal tubules. Whereas, concomitant

Sakr SM and Abdallah WA.

administration of both cyclosporine A and vitamin E resulted in reduction in these histological lesions.

INTRODUCTION

Cyclosporine A (CsA) is an immunosuppressive drug which is used as a primary tool to prevent tissue rejection following solid organ and bone marrow transplantation (Ghalie *et al*, 1994). The ability of CsA to inhibit T cell activation has been shown to have a role in the treatment of many diseases. It is the drug of choice in the treatment of Crohn's disease, ulcerative colitis, biliary cirrhosis, aplastic anaemia, rheumatoid arthritis, myasthenia gravis and dermatomyositis (Niaudet, 1994). Cyclosporine A is also used in the treatment of autoimmune gastritis (Frapien *et al*, 2001).

Some investigators dealt with the adverse effects of cyclosporine A on different systems. Nephrotoxicity is the major side effect of CsA and it occurs in about one-third of all patients. Other adverse effects include gastrointestinal disturbances, hepatotoxicity and neurotoxicity. CsA administration resulted in alteration of renal hemodynamics which resulted in reduced blood flow and a decrease in the glomerular filtration rate. (Curtis *et al*, 1986). The use of cyclosporine A is also associated with nephrotoxicity which is characterized by fluid retention, increase in serum creatinin, increase in urea concentration and a reduction in sodium and potassium excretion (Scott and Higenbottan 1988). The adverse effects of CsA can range from dose-limiting nephrotoxicity and central nervous system effects to cosmetic changes. Some degrees of renal dysfunction occur in up to 40% of patients. Reduction in the glomerular filtration rate and tubular atrophy were also seen in their biopsies (Hultson *et al*, 1994).

Many studies had been performed to minimize the adverse effects of cyclosporine A on the different tissues. Provided evidences showed that the antioxidant effect of vitamin E inhibited lipid peroxidation and limited cyclosporine A related to renal injury (Wang and Salahudeen, 1995). Moreover, Durak, *et al* (1998) concluded that vitamin E in small doses protects the tissue against toxic effects of cyclosporine A.

So the aim of the present study is to investigate the effect of cyclosporine A on the structure of the kidney of adult male albino rats, and to evaluate the effect of vitamin E against these lesions.

Comparative Studies Between...

MATERIAL and METHODS

Twenty male adult albino rats, weighing 200-250 gm were used in this study. The animals were classified into four groups (five animals each).

Group I :

Control group: included rats which received daily oral equivalent amounts of olive oil (the vehicle) for four weeks.

Group II :

Comprised rats which were given daily oral doses of vitamin E (400 mg/kg body weight) for four weeks. (Ebrahim et al, 1996).

Group III :

Included rats which received cyclosporine A orally in a dose 10 mg/kg body weight daily for four weeks. (Paget and Barnes 1964).

N.B.: 25 mgs of CsA were dissolved in 5 ml of olive oil, so as the concentration was 5 mg/ml.

Group IV:

In which the rats were given both vitamin E and cyclosporine A concomitantly as the same doses and duration previously described in groups II and III.

All the animals received balanced diet and they were kept under the same circumstances. At the end of the experiment, the rats were sacrificed, then their kidneys were dissected out.

I- Histological study: The kidneys were fixed in 10% formol saline. The specimens were processed to paraffin sections 5-7 μ m in thickness. They were stained by the following stains.

- (1) Haematoxylin and Eosin. (Drury and Wallington, 1980).
- (2) Periodic acid Schiff's stain. (Cook, 1974).
- (3) Mallory triple stain. (Weesner, 1968).
- (4) Pritchard's technique for mitochondria. (Malaty, 1972).

II- Histochemical study:

Fresh frozen sections were also prepared and they were stained to localize the site and the intensity of acid phosphatase enzyme. (Cook, 1974).

N.B.: Control sections were incubated in an incubating medium lacking the substrate.

Sakr SM and Abdallah WA.

RESULTS

I- Histological results:

Group I: (Control group):

The histological sections of the kidney of these rats showed that the kidney is formed of an outer cortex and an inner medulla. The cortex appeared to be formed of the renal corpuscles, proximal and distal convoluted tubules. The renal corpuscle consisted of a lobulated glomerulus which is surrounded by Bowman's capsule. The parietal layer of Bowman's capsule is lined by flat squamous epithelium. The proximal convoluted tubule (P.C.T.) is lined by a single layer of cuboidal cells enclosing a narrow lumen (Figs. 1 & 2). The tubules are surrounded by PAS positive basement membranes. The apical brush borders of their lining cells exhibited dense reaction for PAS stain (Fig. 3). The distal convoluted tubules (D.C.Ts) are lined by cubical cells surrounding slightly wider lumen than that of the P.C.Ts. (Figs. 1 & 2). Few collagenous fibres are seen in the glomeruli and inbetween the cortical tubules (Fig. 4). The basal parts of the cytoplasm of both P.C.Ts and D.C.Ts contained blackish granules of mitochondria (Fig. 5). The parenchyma of the medulla consisted of the collecting tubules and the thick and the thin limbs of loop of Henle (Fig. 6).

Group II :

Included animals which received vitamin E only. The histological picture of the kidney was similar to that observed in control rat. Positive PAS reaction in the brush borders of P.C.T cells as well as the mitochondrial content in the cytoplasm of both P.C.T. and D.C.T cells are similar to control sections with densely stained brush borders and basement membranes. Their collagenous fibres are nearly as in control sections.

Group III:

Included rats treated with CsA only, there are patchy areas of lesions. Most of the glomeruli were hypertrophied with obliteration of their Bowman's space (Fig. 7). Whereas, other glomeruli were atrophied with widening of their Bowman's space. (Fig. 8). Dilatation of most of the distal convoluted tubule with flattening of their lining cells (Figs. 8 & 9). Dilatation of some of the proximal convoluted tubules with vacuolation of their cytoplasm were seen (Fig. 10).

Mononuclear cellular infiltration was also noticed (Fig. 10). The cytoplasm of the cortical tubules showed reduction in its mitochondrial

Comparative Studies Between...

content (Fig. 11). In PAS stained section, there was an increase in the thickness of the glomerular and tubular basement membranes (Fig. 12). Decrease in the intensity of the PAS reaction in the brush borders of P.C.T cells was also noticed (Fig. 13). In the medulla of the kidneys of these rats acidophilic hyaline casts were seen in the lumen of the collecting tubules (Fig. 14). The cells of the collecting tubules are highly vacuolated. They show faintly stained cytoplasm and pyknotic nuclei. Different tubules are dilated with disturbed architecture and haemorrhagic areas are also seen (Fig. 15).

In Mallory stained sections, there was an increase in the collagen contents in the glomeruli and around the renal tubules (Fig. 16). Increase in collagenous fibres was also observed around the medullary tubules. Interstitial haemorrhage was seen between these medullary tubules (Fig. 17).

Group IV:

This group comprised rats treated with both cyclosporine A and vitamin E. The kidneys of these rats are nearly similar to that seen in control group. The renal corpuscles and the renal tubules appeared with normal profile, while some pyknotic nuclei could be observed (Fig. 18). The cytoplasm of the cortical tubules showed a decrease in the mitochondrial content compared with control group (Fig. 19), these tubules were surrounded by thin PAS positive basement membranes. The apical brush borders of P.C.T cells exhibited strong PAS positive reaction (Fig. 20).

II- Enzyme histochemical results :

Examination of the sections of the kidneys of animals of control group showed strong reaction for acid phosphatase enzyme activity in the cytoplasm of the P.C.T. cells especially in their basal parts (Fig. 21). Strong reaction for the enzyme activity was also seen in sections of animals of group II. Whereas, marked reduction in the activity of the enzyme was noticed in sections of rats of group III, which received CsA only (Fig. 22). Concomitant administration of both CsA and vitamin E. resulted in moderate reaction for acid phosphatase compared with the control group (Fig. 23).

DISCUSSION

This study was done to observe the renal lesions caused by cyclosporine A administration and to detect the effect of vitamin E against

Sakr SM and Abdallah WA.

these lesions. In animals of group II, which received olive oil only, no histological lesions could be seen in their kidneys. It was suggested that olive oil had no adverse effect on the structure of the kidney. Whereas, the kidneys of animals received CsA only showed patchy areas of lesions. There was hypertrophy of some glomeruli, while others were atrophied. Increase in the thickness of the glomerular basement membrane and increase in the collagen content of these glomeruli were also noticed. Similar findings were seen by Potiet *et al.*, (1996). They came to the conclusion that CsA caused contraction of the glomeruli. It was suggested that these glomerular lesions might result in alteration of the blood-renal barrier with subsequent reduction in the glomerular filtration rate. The same explanation was previously discussed by many authors. Burrows and Davis (1978) concluded that thickening of the glomerular basement membrane may alter the capacity of the blood renal barrier for filtration. Curtis *et al.*, (1986) stated that cyclosporine A administration resulted in fall in the glomerular filtration rate which was resulted in acute nephrotoxicity. Moreover, Scott and Higenbotton (1988) reported that the use of CsA was associated with nephrotoxicity which was characterized by an increase in both serum creatinine and urea concentration in the blood.

It was also seen that the increase in the thickness of the glomerular basement membrane might result in failure of the glomeruli to reabsorb microalbumin resulted in microproteinuria. This was in accordance with the finding of Bolton, *et al.*, (1976). They stated that thickening of the glomerular basement membrane caused an increase in its permeability to protein. It was suggested that the non-reabsorbed protein might be precipitated in the lumen of the renal tubules which was seen as acidophilic casts in the tubules of animals of group III.

The proximal convoluted tubules of the kidneys of animals of group III (which received CsA only) showed some dilatation with vacuolation of the cytoplasm. Decrease in the PAS positive reaction was seen in the brush borders of their lining cells. Increase in the thickness of the tubular basement membrane was also noticed. The same results were noticed by Whitney *et al.*, (1982). They concluded that CsA has a direct toxic action on the renal tubular epithelium resulted in cytoplasmic vacuolation and tubular cell necrosis. Moreover, Schechter (1996) reported that CsA toxicity is associated with fatal tubular necrosis. Marked reduction in the mitochondrial content of the cytoplasm of the cortical tubules was also observed in the kidneys of rats which received CsA. The same result was seen by Elzinga *et al.*, (1989). They proved that CsA caused impaired mitochondrial function and mitochondrial damage which play a

Comparative Studies Between...

pathogenetic role in events leading to cell death. Cormack (1987) stated that one of the function of the P.C.T. cells is the reabsorption of protein. It was seen that the observed lesions seen in the P.C.Ts might result in deterioration of their functions leading to loss of protein in urine (proteinuria). Reduction in the acid phosphatase activity was also observed in the P.C.T. cells of the kidneys of animals of group III (which received CsA only). It was suggested that the observed reduction in acid phosphatase activity might result from the decrease in protein reabsorption by the P.C.T cells. Fawcett (1986) stated that the reabsorbed protein by the P.C.T cells was positive for acid phosphatase.

In the kidneys of rats of group III, there were dilatation of the distal convoluted tubules with an increase in the thickness of their basement membrane. Reduction in the mitochondrial content was also noticed in the cytoplasm of their cells. It was seen that the dilatation of the D.C.Ts might be a sign of glomerulonephritis caused by CsA as described by William (1976), who stated that the glomerulonephritis was associated with dilatation of the tubules. It was also suggested that these lesions of the D.C.Ts might alter sodium and water reabsorption by these tubules resulting in polyuria. This was in agreement with the observations of Hultson, *et al.*, (1994), who stated that CsA can cause some degree of renal dysfunction and nephrotoxicity.

The kidneys of animals of group III which received CsA, showed mononuclear cellular infiltration with increase in the collagen content around the renal tubules. The same picture of interstitial fibrosis was also described by Keown, (1991) who stated that the arteriolar vasoconstriction might be the cause of chronic ischemia which results in fibrosis around the renal tubules in CsA treated rats. Versluis *et al.*, (1988) added that interstitial fibrosis and cellular infiltration might occur as a reaction against progressive epithelial cell death and atrophy of the nephron.

There was also dilatation of the collecting tubules in the kidneys of CsA treated rats. It was seen that these dilatation might occur secondary to the interstitial oedema and failure of these tubules to reabsorb water. This explanation was supported by the results of Scott and Higenbottan (1988), who stated that the use of CsA is associated with fluid retention.

Many authors discussed the mechanisms by which CsA can cause its toxicity. Duarte (1985) stated that CsA caused arteriolar vasoconstriction due to inhibition of renal prostaglandin synthesis which is needed to maintain glomerular perfusion. Moreover, Zoal *et al.*, (1988) stated also that CsA may induce arteriolar damage via the endothelial cells which are the first target for CsA. However, Lucey *et al.*, (1990) concluded

Sakr SM and Abdallah WA.

that CsA can cause its toxicity due to accumulation of its toxic metabolites, resulting in renal dysfunction. Salahudeen (1992) proved that the accumulation of CsA in the kidney may induce local peroxidation of cellular lipid with several possible effects including direct cellular toxicity. Cyclosporine A produces reduction in the renal microsomal protein synthesis, which could be the direct cause of acute renal dysfunction (Bennet *et al.*, 1991).

Deray *et al.*, (1992) and Tariq *et al.*, (1999) concluded that CsA induced toxicity due to reduction in blood flow which leads to hypoxic injury which is accompanied by excessive generation of oxygen derived free radicals. Moreover, Baud and Ardaillou (1993), stated that when the amount of oxygen derived free radicals exceed the capacity of the cells or organ antioxidant system, the normal function of these cells is disrupted and tissue damage develops. Concomitant administration of both CsA and vitamin E in animals of group V, showed marked improvement in the renal lesions induced by cyclosporine A.

So, it was suggested that CsA produced its lesion in animals of group III through the production of oxygen-derived free-radicals, and vitamin E with its antioxidant effect has a protective role against these lesions. The same explanation for the protective role of vitamin E was discussed by Inselmarm *et al.*, (1990), who stated that vitamin E through its antioxidant defense mechanism can make the renal tissue more vulnerable to the toxic effects of the free radicals. Moreover, Wang and Salahudeen (1995) provided evidence that the antioxidant effect of vitamin E inhibited lipid peroxidation and limited Cyclosporine A related renal injury. In addition, Durak *et al.*, (1998) and Kumar *et al.*, (1999) stated that vitamin E acts as a lipid - radical scavenger and it has a protective role against cyclosporine A nephrotoxicity as it protects the renal tissue.

From this study, it was seen that cyclosporine A can cause renal lesions and renal dysfunction, but Vitamin E can protect the kidney tissue from these lesions, so it is recommended to give vitamin E. supplementation to those patients treated with cyclosporine A to minimize its toxic effect of the renal tissue.

REFERENCES

Baud, L. and Ardaillou, R. (1993): Involvement of reactive oxygen species in kidney damage. *Br. Med. Bull.* (49) 621-629.

Bennet, W.N., Houghton, D.C. and Buss, W.C. (1991): Cyclosporine A - induced renal dysfunction: Correlation between cellular events and whole kidney function. *J. Ana. Soc. Nephrol.* 1(11) 1212-1219.

Comparative Studies Between...

Bolton, W.K., Benton, F.R., Maclay, J.G. and Sturgill, B.C. (1976): Spontaneous glomerular sclerosis in aging Sprague - Dawely rats. *Am. J. Path.* (85) 272-275.

Burrows, G.D. and Davis, B. (1978): Unique tubular lesions after lithium. *Lancet* 917) 1310-1311.

Cook, H.C. (1974): "Manual of Histological Demonstration Techniques" Butterworth, London.

Cormack, H.D. (1987): Ham's Histology, ninth edition, J.B. Lippincott Company, Philadelphia, London.

Curtis, J.J., Dubovsky, E and Whelchel, J.P. (1986): Cyclosporine in therapeutic doses increases renal allograft vascular resistance. *Lancet*, (2) 447.

Deray, G., Benkmida, M., le Hoang, P., Maksud, P., Aupetit, B., Baumelou, A and jacobs; C. (1992): Renal function and blood pressure in patients receiving long-term cyclosporine therapy. *Ann. Intern. med.* (117) 578-583.

Drury, R.A. and Wallington, E.A. (1980): "Carlton's Histological Techniques" 5th edition, Oxford University.

Duarte, R. (1985): Cyclosporine, renal effects and prostacyclin. *Ann. Intern. Med* (102) 420.

Durak, I, Karaback, H.I., Buyukocak, S., Cimen, M.Y., Kacmaz, M., Omerglu, E and Ozturk, S. (1998) : Impaired antioxidant defense system in the kidney tissue from rabbit treated with cyclosporine. *Nephron* (78) 207-211.

Ebrahim, A.S., Babakrishnam, K. and Sakthisekeram, D. (1996): Perchloroethylene - induced alterations in glucose metabolism and their prevention by 2-deoxy. D-glucose and Vitamin E in mice *J. App. Toxicol.* Vol. 1694) 339-348.

Elzinga, L.W., Mela-Riker, L.M., Widenea, L.L. and Bennett, W.M. (1989) : Renal cortical mitochondrial integrity in experimental cyclosporine nephrotoxicity. *Transplantation.* 4B (1) 102-106.

Fawcett, D.W. (1986): "A Textbook of Histology" eleventh edition W.B. Saunders Company, Hong Kong.

Frapien, J., Choby, C., Mangoni, M., Nargeot, J., Albat, B. and Richard, S. (2001): Cyclosporine A increases basal intracellular calcium

Sakr SM and Abdallah WA.

and calcium responses to endothelium and vasopressin in human coronary myocytes. *FEBS*, (493) 57-62.

Ghalie, R., Fitzsimons, W.E. and Weinstein, A. (1994): Cyclosporine A monitoring improves graft-versus host disease prophylaxis after bone marrow transplantation. *Ann. Pharmacol.* (28) 379-383.

Hultson, S.A., Jadresic A., and Land Shah, V. (1994); Effect of cyclosporine A on glomerular filtration rate in children with minimal change nephrotic syndrome. *Pediatric Nephrol.* (8) 404-407.

Inselmarm, G., Hanneimann, J. and Baimnk, C. (1990): Cyclosporine A induced lipid peroxidation and influence on glucose 6 phosphatase in rat hepatic and renal microsomes. *Res. Commun. Chem. Pathol. Pharmacol.* (68) 189-203.

Keown, P.A. (1991): The physiological basis of experimental cyclosporine nephrotoxicity. *Transplantation.* (6) 1.

Kumar, K.V., Naidu, M.U., Shifow, A.A., Prayag, A and Ratnakar, K.S. (1999): Melatonin, an antioxidant protects against cyclosporine induced nephrotoxicity. *Transplantation* 915) 67 (7) 1065-1068.

Lucey, M.R., Kolars, J.C., Merion, R.M., Campell, D.A., Aldrich, M. and Watkins, P.B. (1990): Cyclosporine toxicity at therapeutic blood levels and cytochrome P-450 IIIa. *Lancet* (335) 11-15.

Malaty, A.M. (1972): The effect of oral antidiabetics on liver, kidney, cerebellum and pancreas in normal and experimentally induced diabetic rabbits. *Medicine, M.D., Thesis, Alexandria University.*

Niaudet, P. (1994): Treatment of childhood steroid-resistant idiopathic nephrosis with a combination of Cyclosporine and Prednisone. *J. Pediatr.* (125) 981-986.

Paget, G. and Barnes, J. (1964): Evaluation of drug activities. Vol. I; Academic Press.

Potiet, M., Winicki, J. and Camber, J. (1996): Nitric oxide (NO) donor 3- morpholinonimine antagonizes cyclosporine A induced contraction in two in vitro glomerular models. *Cell. Biol. Toxicol.* (12) 4-6 335-339.

Salahudeen, K. (1992): Novel, 21 aminosteroid inhibits H₂O₂ induced lipid peroxidation and prevents renal epithelial cell injury. *J. Am. Soc. Nephrol.* (3) 714.

Comparative Studies Between...

Schechter, P. (1996): Acute tubular necrosis following high-dose cyclosporin A therapy. *Eur. J. Clin. Pharmacol.* 49, 521-523.

Scott, J.P. and Higenbottan, T.W. (1988): Adverse reactions and interactions of cyclosporine A. *Med. Toxicol.* (3) 107-127.

Tariq, M., Morais, C., Sobki, S., Al-Sulaiman, M. and Khader, A.A. (1999): N-acetylcystein attenuate cyclosporine-induced nephrotoxicity in rats. *Nephrol-Dial. Transplant.* (14) 923-929.

Versluis, D.J., Tenkate, F.J., Weening, G.J., Jeekel, J. and Weimar, W. (1988): Histological lesions associated with cyclosporine incidence and reversibility in one year old kidney transplantation. *J. Clin. Pathol.* 41(5) 498-503.

Wang, C and Salahudeen, A.K. (1995): Lipid peroxidation accompanies cyclosporine nephrotoxicity. Effects of vitamin E. *Kid. International.* (47) 927-934.

Weesner, F.M. (1968): "General Zoological Microtechniques" Copyright, Sicientific Book Agency, Calcutta.

Whitny, P.H., Thomson, A.W., Blair, J.t. and Simpson, J.G. (1982): Epixerimental cyclosporine A nephrotoxicity. *Br. J. Exp. pathol.* 63-88.

William, B (1976): A textbook of Pathology, Structure and function in diseases. Eighth edition, Great Britain, London.

Zoal, M.J. Vries, J.D. and Boen, Y.T. (1988): Is cyclosporine A toxic to endothelial cells. *Lancet* (22), 956-957.

Sakr SM and Abdallah WA.

FIGURE CAPTIONS

Fig. (1):

A photomicrograph of a section of the kidney of control rat, showing the renal corpuscles (R), the proximal convoluted tubules (P) and the distal convoluted tubules (d).

*H & E
X250
Group I*

Fig. (2):

A photomicrograph of a section of the kidney of the control rat. The renal corpuscle is formed of a glomerulus (G) surrounded by Bowman's space. (S). The proximal convoluted tubules (P) and the distal convoluted tubules (d) are obvious.

*H & E
X640
Group I*

Fig. (3):

A photomicrograph of a section of the kidney of the control animal, showing thin, PAS positive tubular and glomerular basement membranes. The apical brush borders of the P.C.T cells exhibit positive PAS reaction (↑).

*PAS X
250
Group I*

Fig. (4):

A photomicrograph of a section of the kidney of the control rat, showing few collagenous content in the glomeruli and around the renal tubules.

*Mallory stain
X 250
Group I*

Fig. (5):

A photomicrograph of a section of the kidney of a control rat, showing mitochondrial content in both P.C.Ts. and D.C.Ts.

*Pritchard's
technique X 640
Group I*

Comparative Studies Between...

Fig. (6):

A photomicrograph of a section of the kidney of a control animal, showing normal profile of the medullary tubules.

H & E
X250
Group I
Fig. (7):

A photomicrograph of a section of the kidney, showing hypertrophy of the glomeruli with obliteration of their Bowman's spaces.

H&E X 250
Group III

Fig. (8):

A photomicrograph of a section of the rat kidney, showing atrophy of some glomeruli (†). Dilatation of the P.C.Ts. and D.C.Ts is obvious (d).

H&E X250
Group III

Fig. (9):

Higher magnification for another section of the rat kidney, showing few degenerated cells and dilatation of the P.C.Ts. and D.C.Ts.(d) with flattening of their lining cells.

H&E X 640
Group III.

Fig. (10):

A photomicrograph of a section of the rat kidney, showing mononuclear cellular infiltration (†). Dilatation of both P.C.Ts and D.C.Ts is obvious. The cytoplasm of the P.C.T. cells is vacuolated. Notice the enlarged glomeruli and the narrow Bowman's spaces.

H & E X250
Group III

Fig. (11) :

A photomicrograph of a section of the rat kidney, showing reduction in the mitochondrial content in the cytoplasm of both P.C.T. and D.C.T. cells.

Pirthcard's
technique X640
Group III

Fig. (12) :

A photomicrograph of a section of the rat kidney. Increase in the thickness of the tubular and glomerular basement membranes is apparent

PAS

Sakr SM and Abdallah WA.

X250
Group III

Fig. (13):

A photomicrograph of a section of the rat kidney, showing reduction in the PAS positive reaction in the brush borders of the P.C.T. cells (↑).

PAS
X250
Group III

Fig. (14):

A photomicrograph of a section of the rat kidney. Acidophilic hyaline casts are seen in the lumen of the collecting tubules.

H & E
X250
Group II

Fig. (15):

A photomicrograph of a section of the rat kidney, showing dilatation of the collecting tubules with faintly stained cytoplasm. Some pyknotic nuclei (py), highly vacuolated cells (V) and haemorrhagic areas (h) are seen.

H & E
X25
Group III

Fig. (16):

A photomicrograph of a section of the rat kidney, showing an increase in the collagen contents in the glomeruli (G) and in between the tubules(1).

Mallory stain
X250
Group III

Fig. (17):

A photomicrograph of a section of the rat kidney, showing an increase in the collagen content in between the medullary tubules. Notice the interstitial haemorrhage.

Mallory stain X250
Group III.

Comparative Studies Between...

Fig. (18):

A photomicrograph of a section of the rat kidney. The renal corpuscle, The P.C.Ts and the D.C.Ts have the same profile as in control rats, while some pyknotic nuclei could be observed (py).

*H & E X640
Group IV*

Fig. (19):

A photomicrograph of a section of the rat kidney, showing the mitochondrial content in the cytoplasm of the P.C.T and D.C.T cells. Note apparent decrease in the mitochondrial content compared to the control.

*Pritchard's technique
X640
Group IV*

Fig. (20):

A photomicrograph of a section of the rat kidney, showing thin PAS positive glomerular and tubular basement membranes. The apical brush borders of the P.C.T cells show normal positive PAS reaction.

*PAS X250
Group IV*

Fig. (21) :

A photomicrograph of a section of the rat kidney, showing strong positive reaction for acid phosphatase enzyme activity in the cytoplasm of the P.C.T cells. The renal corpuscles and the D.C.Ts are negative for the reaction.

*Lead phosphate
technique X250
Group I*

Fig. (22):

A photomicrograph of a section of the rat kidney, showing marked reduction in the acid phosphatase activity in the P.C.T. cells.

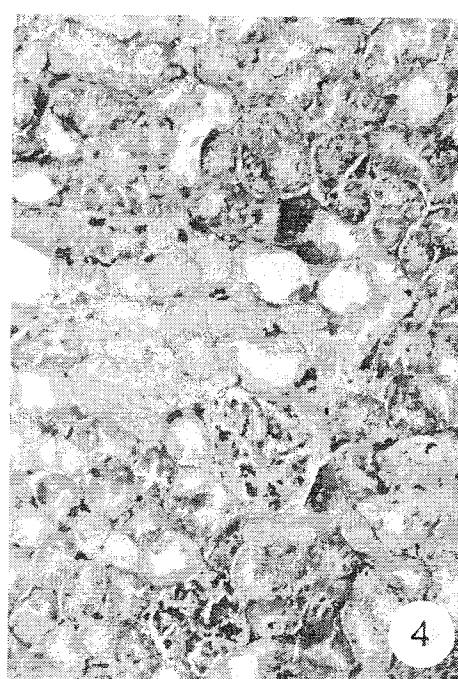
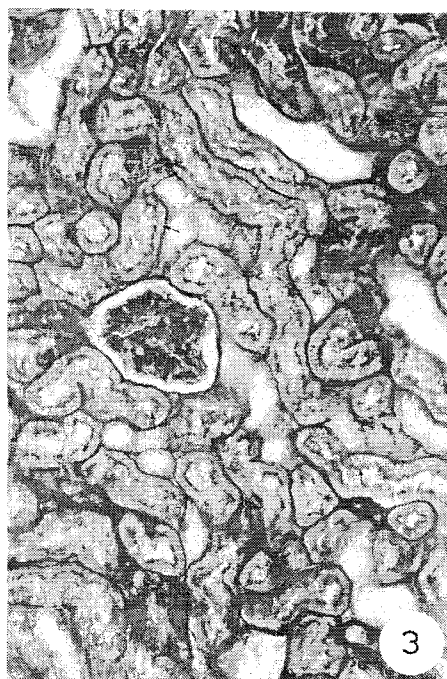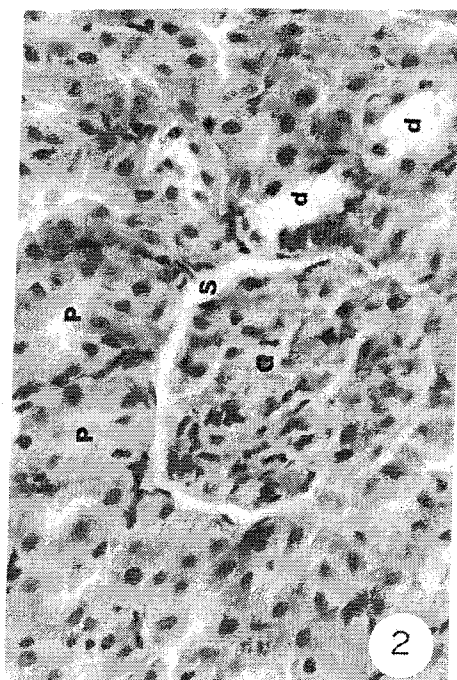
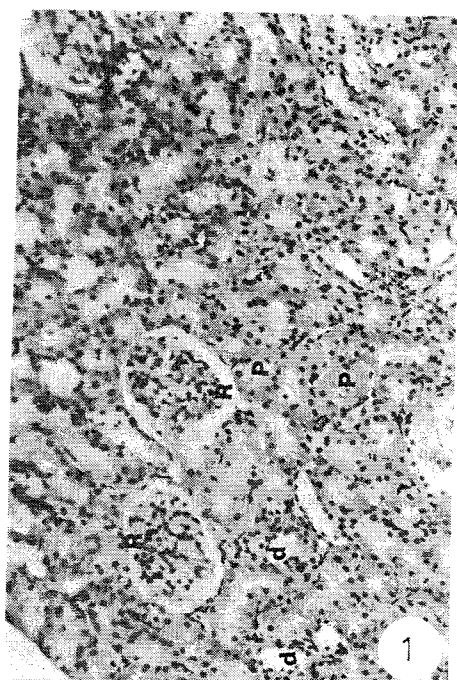
*Lead phosphate
technique X250
Group III*

Fig. (23):

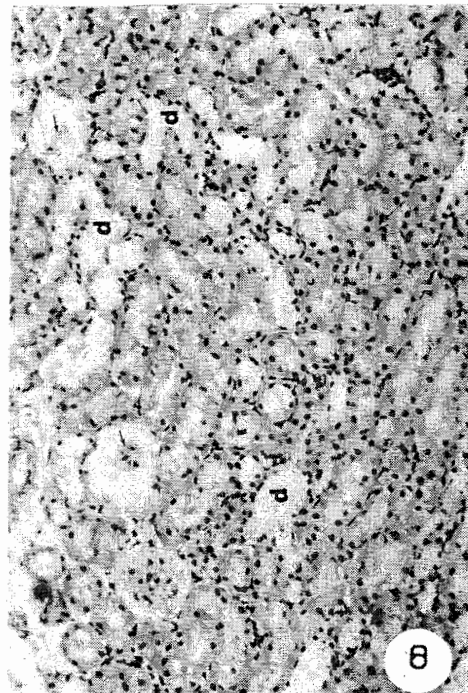
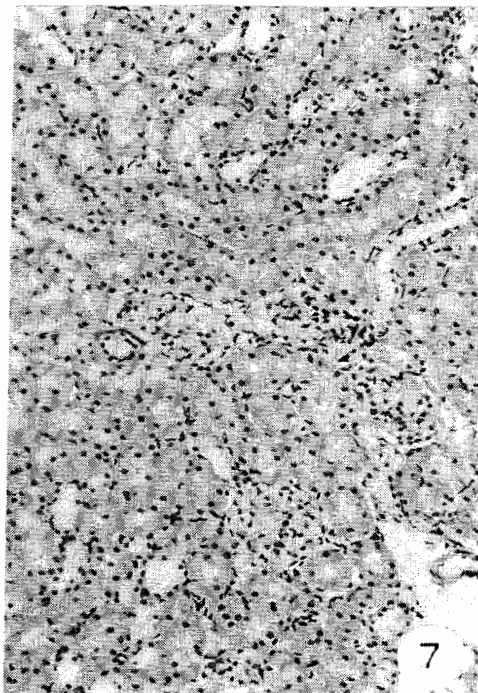
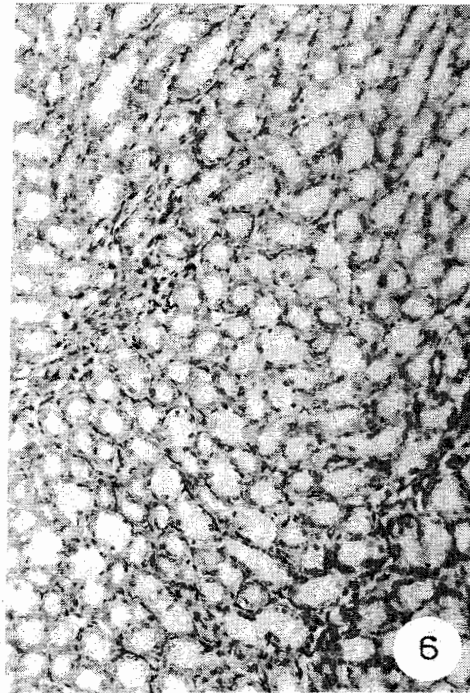
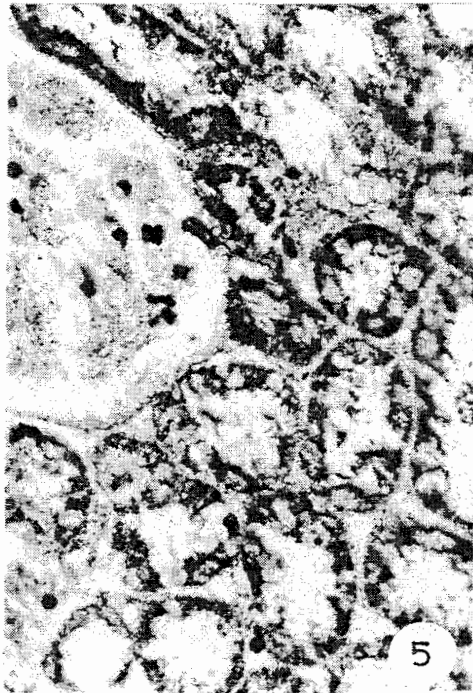
A photomicrograph of a section of the rat kidney, showing moderate acid phosphatase activity compared with control group.

*Lead Phosphate
technique X250
Group IV*

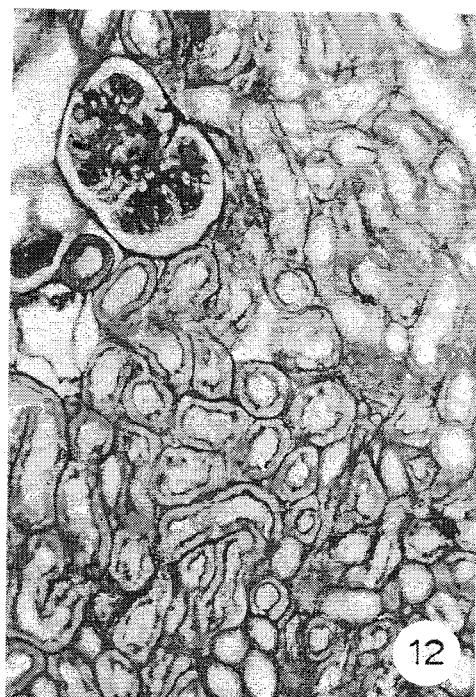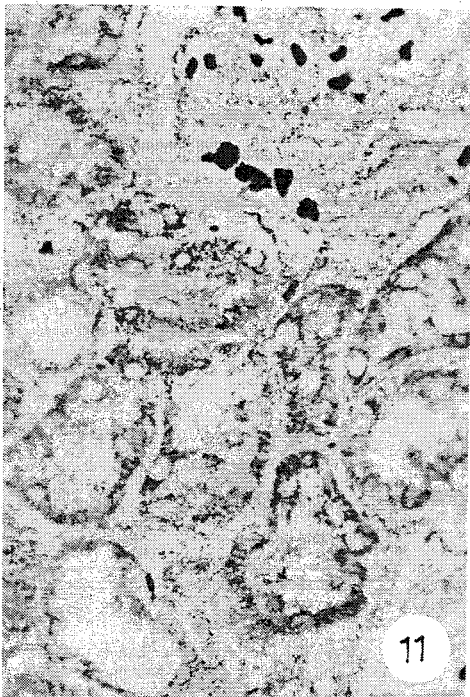
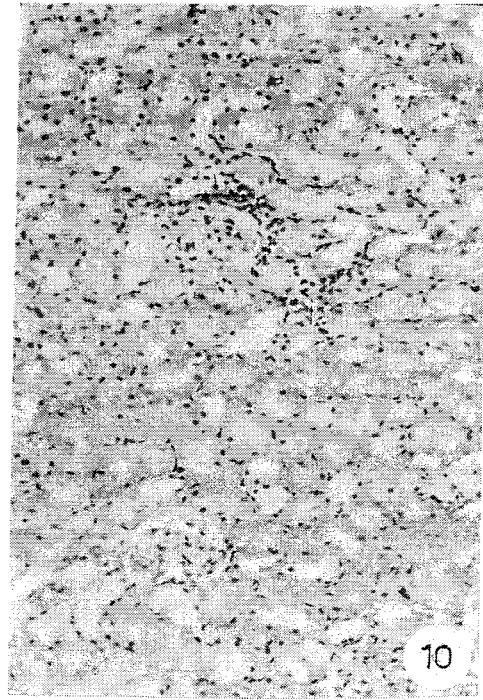
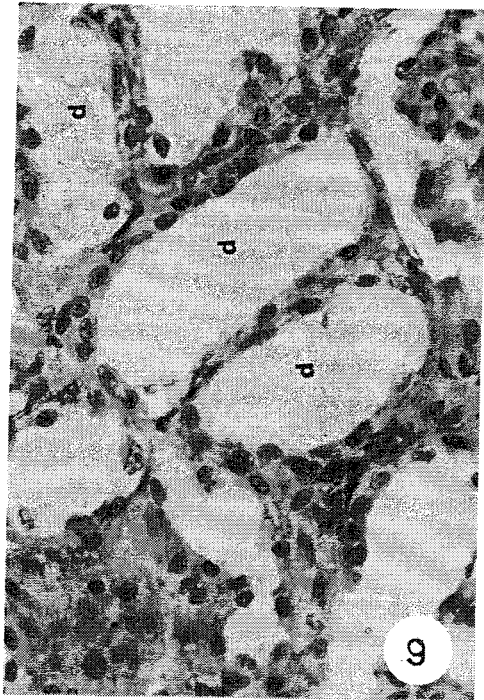
Sakr SM and Abdallah WA.



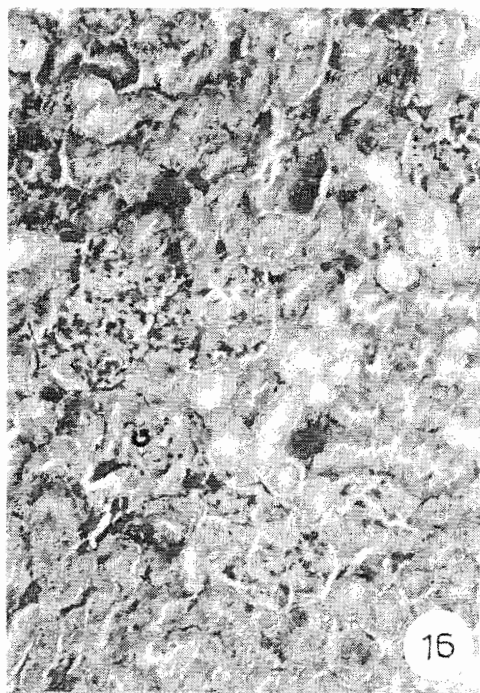
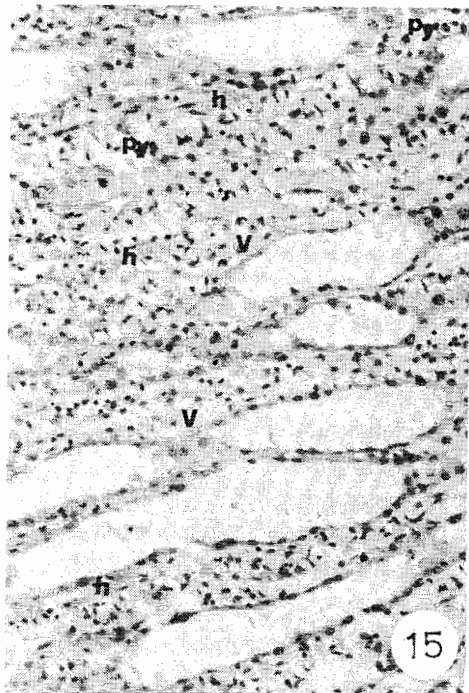
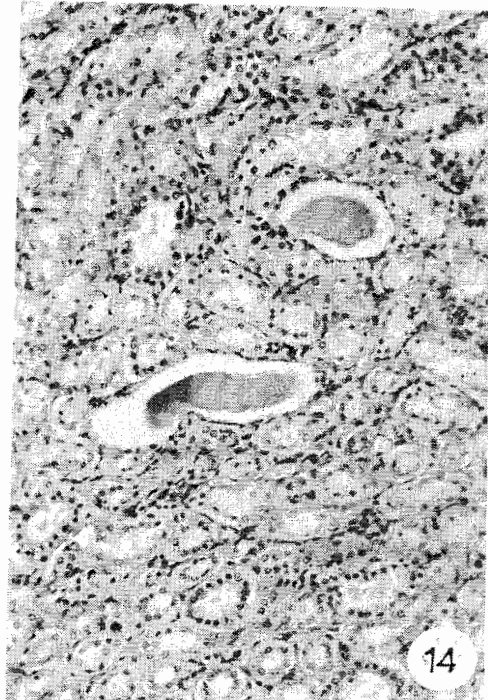
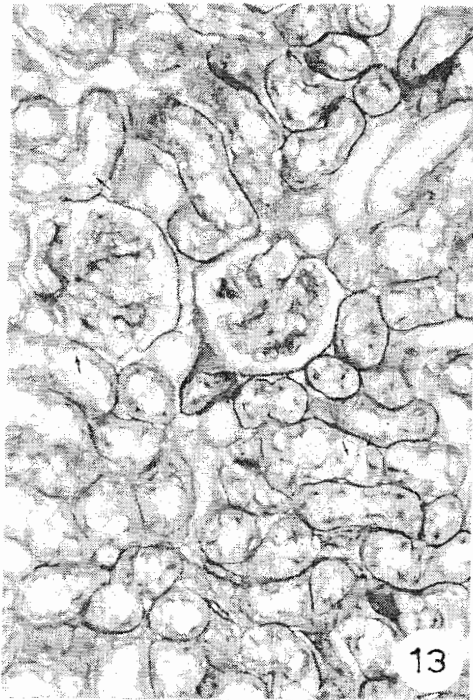
Comparative Studies Between...



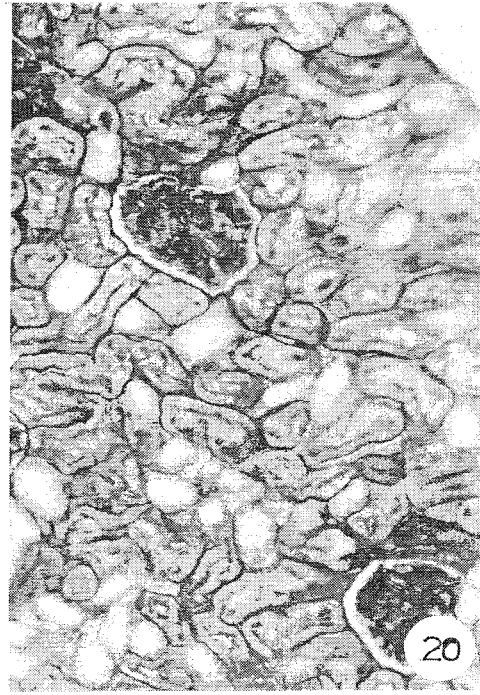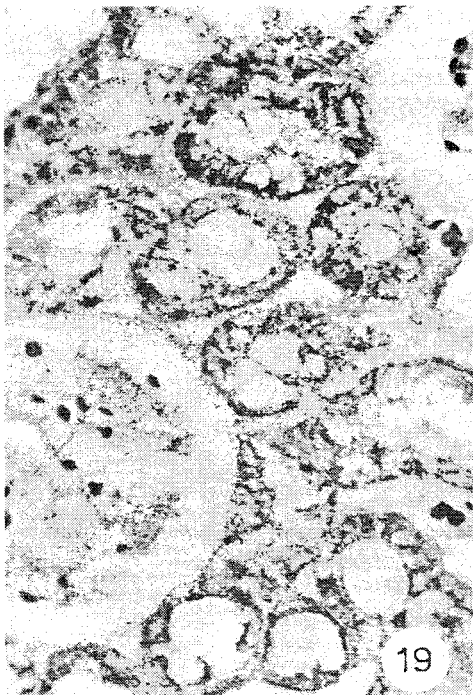
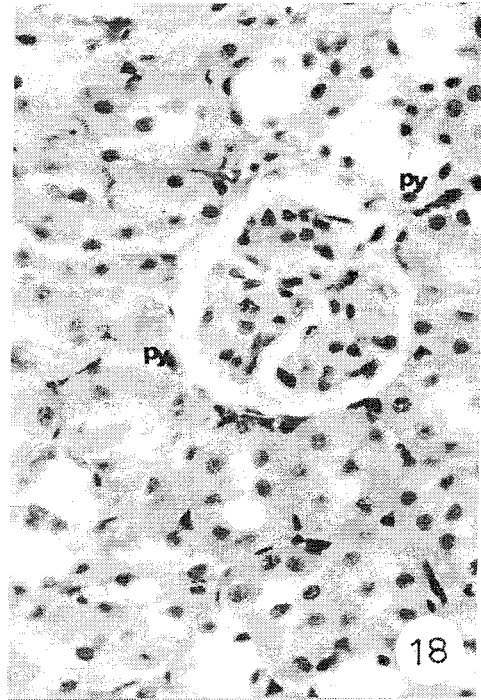
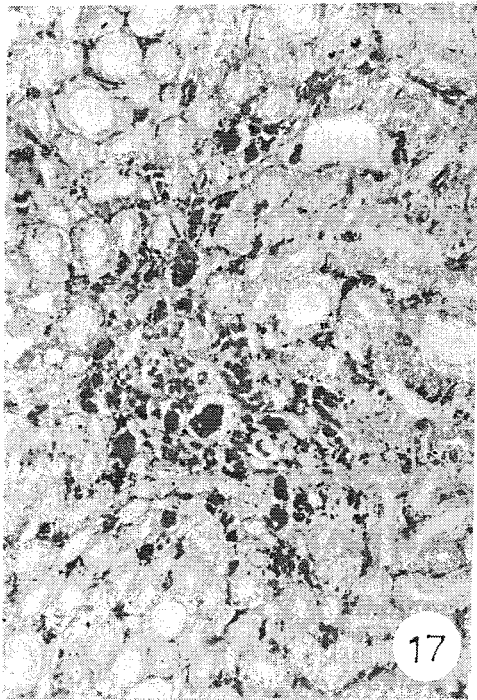
Sakr SM and Abdallah WA.



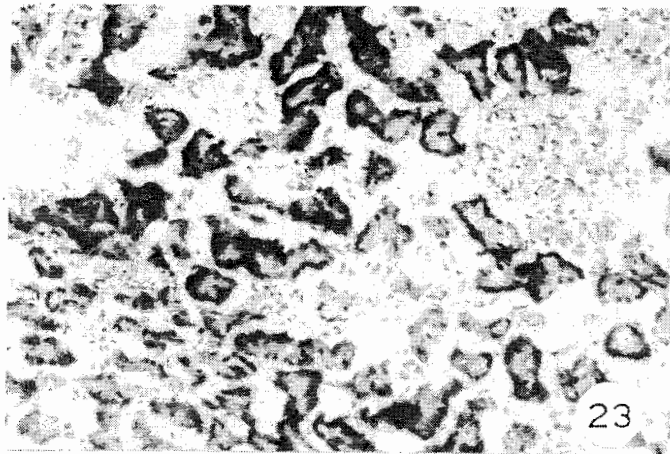
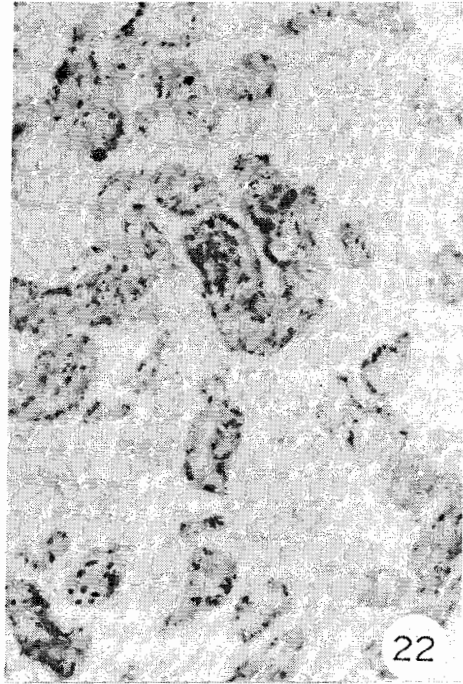
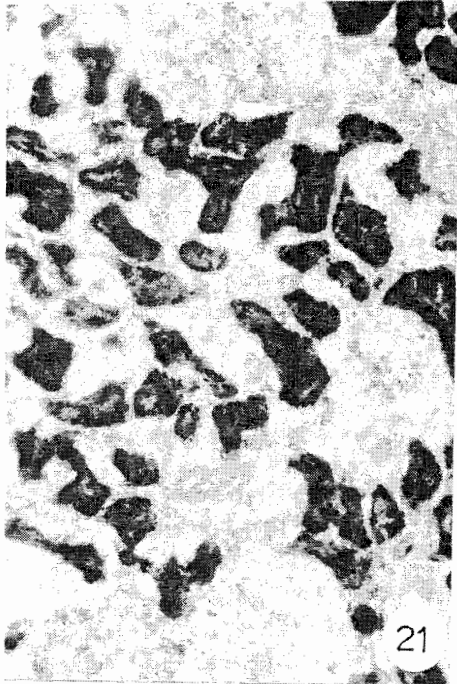
Comparative Studies Between...



Sakr SM and Abdallah WA.



Comparative Studies Between...



دراسات مقارنة عن تأثير عقار السيكلوسبورين أ و فيتامين هـ على كلية ذكر الجرذ الأبيض البالغ (دراسات هستولوجية وهستوكيميائية)

واصف عبد الحليم عبد الله* - سامية محمد صقر**
*قسم علم الحيوان - كلية العلوم - جامعة الأزهر
**قسم العلوم البيولوجية - كلية التربية - جامعة عين شمس

يعد السيكلوسبورين أ عقار مثبط للمناعة ويستخدم في علاج الأمراض المناعية وفي حالات لفظ الأنسجة بعد عمليات زرع الأعضاء ولقد أجريت هذه الدراسة لتتبع إصابات الكلى المستحثة بالسيكلوسبورين أ ودور فيتامين هـ ضد هذه التغيرات ولقد استخدم في هذا البحث عشرون جرذاً أبيضاً من الذكور البالغة وقسمت هذه الحيوانات إلى أربع مجموعات (خمس حيوانات لكل مجموعة)

المجموعة الأولى : المجموعة الضابطة : وبها الحيوانات التي أعطيت كميات معادلة من زيت الزيتون يومياً ولمدة أربعة أسابيع عن طريق الفم

المجموعة الثانية : واشتملت على الحيوانات التي أعطيت جرعات فيتامين هـ يومياً عن طريق الفم 400 مجم / لكل كيلوجرام من وزن الجسم لمدة أربعة أسابيع

المجموعة الثالثة : وفيها الحيوانات التي أعطيت جرعات يومية من السيكلوسبورين أ عن طريق الفم ، 10 مجم لكل كيلو جرام من وزن الجسم لمدة أربعة أسابيع

المجموعة الرابعة : واشتملت على الحيوانات التي أعطيت كل من السيكلوسبورين أ وفيتامين هـ معاً وبنفس الجرعات والمدة السابقة مثل المجموعات الثانية والثالثة

ونقد أظهر فحص كلية الحيوانات التي أعطيت السيكلوسبورين أ عن وجود تغيرات هستوباثولوجية في أماكن متفرقة بها وكانت معظم الكبات الكلوية متضخمة وأخرى ضامرة مع وجود اتساع في كل من الأنابيب المعوجة القريبة والبعيدة. وظهر ارتشاح خلوي أحادي النواة بين الأنابيب الكلوية وظهرت أيضاً قوالب شفافة محبة للصبغة الحمضية في تجويف الأنابيب الجامعة. كما كان هناك نقص في تفاعل الجزء القمي لخلايا الأنبوب المعوج القريب لصبغة البير أيودك أسيد شيف مع زيادة في سمك الغشاء القاعدي لهذه الأنابيب وأيضاً في الغشاء القاعدي للشعيرات الدموية في الكبات الكلوية. وأوضحت الدراسة أيضاً عن وجود نقص في الأجسام الخيطية لسيتوبلازم خلايا الأنابيب المعوجة. مع نقص في نشاط الأنزيم الفوسفاتيزي الحامضي وزيادة في محتوى الكولاجين في الكبات الكلوية وأيضاً حول الأنابيب الكلوية ولقد أدى استخدام كل من السيكلوسبورين أ وفيتامين هـ معاً في هذه الدراسة عن إختفاء هذه التغيرات الهستولوجية للكلية