



Scientific Journal of Faculty of  
Science (Menoufia University)  
ISSN: 1110-2195



## Effect of ginger on gabapentin-induced morphological and skeletal abnormalities in the chick *Gallus domestics*

Gamal M Badawy<sup>1</sup>, Marwa N Atallah<sup>1\*</sup>, Saber A Sakr<sup>1</sup>

<sup>1</sup>Zoology Department - Faculty of Science - Menoufia University, Egypt.

\*Correspondence

Email: [marwa.atallah@science.menoufia.edu.eg](mailto:marwa.atallah@science.menoufia.edu.eg)

**Abstract:** Epilepsy is associated with an increased risk of having malformed children. Gabapentin (GBP) is a new generation antiepileptic drug and categorized as 'C' considering its possible teratogenic risk. The present study adopted two integrated aspects. The first has dealt with investigating the possible toxic side effects of GBP on the developing chick embryos in terms of morphological and endo-skeletal studies. The second examined the possible ameliorative effect of ginger water extract against the toxicity induced by GBP injection. Injection of GBP resulted in adverse effects in chick embryos at different levels. Morphologically, the chick embryos suffered from significant growth retardation and various morphological malformations such as omphalocele, limb deformities, short beak and subcutaneous hemorrhage. The endoskeleton showed different alterations including kyphosis, caudal regression syndrome kinked tail and pygostyle, loss of some bone. In addition, there was reduction in the ossification centers of long bones. Co-injection of ginger along with GBP decreased the incidence of most morphological and endo-skeletal alterations, furthermore, increased the length of ossification centers in long bones compared with GBP alone. In conclusion, the use of GBP as an AED should be treated with highly caution during pregnancy and ginger is recommended to be taken in parallel for its ameliorative role in this regard.

*Keywords: ginger influence, chick Gallus domestics, experimental study*

## 1. Introduction

Epilepsy affects millions of people all over the world. Its seriousness lies in the fact that most of the epileptic women need to continue taking medication during pregnancy, since uncontrolled seizures may have a deleterious effect on the women as well as their fetuses (Perucca 2005; Tomson and Battino, 2012; Akhtar *et al.*, 2015).

Currently, management of epilepsy mainly depends on antiepileptic drugs (AEDs), which are notoriously known for their adverse side effects (Meador, 2008). Infants of mothers treated with AEDs during pregnancy had a greater incidence of congenital malformations than those of either normal controls or non-treated epileptic women (Etemad *et al.*, 2013).

In the recent years, numerous drugs have been introduced to the treatment of epilepsy. AEDs generally may be divided to the older, classic AEDs and the newer, next generation AEDs. The adverse effects of old drugs are well known, whereas those of the newer drugs are much less recognized (Verrotti *et al.*, 2010). Gabapentin (GBP) is a new generation AED which was originally introduced for the treatment of epilepsy but has achieved greater popularity as an adjunctive therapy for chronic pain and categorized as 'C' considering its possible teratogenic risk by FDA (Krasowski, 2010; Nasar *et al.*, 2014; Singh *et al.*, 2014). Clinically, GBP is indicated as an add-on medication for the treatment of partial seizures and neuropathic pain as well as prophylaxis of migraine (Afshar *et al.*, 2009).

GBP is relatively a new agent of a typical antiepileptic class and. Due to its low molecular weight (171 Da) and poor binding capacity to plasma protein, it crosses easily the placental membrane and blood–brain barrier (Ochoa, 2008). Lack of appreciable metabolism, no drug

interaction in the body, rapid glomerular filtration rate, and good tolerance of this drug are reasons for its extensive usage (Tatum *et al.*, 2000). However, despite expanding data on the usage of GBP, there is little information, so far, on its teratogenic effects (Afshar *et al.*, 2009).

It is well documented that antiepileptics belong to the drugs which have traditionally been considered as bone damaging (Mazziotti *et al.*, 2010). Administration of AEDs may lead to the development of osteomalacia (rickets in children) or osteoporosis (Gissel *et al.*, 2007). The axial skeleton is routinely examined in standard developmental toxicity bioassays and has proven to be sensitive to a wide variety of chemical agents (Fadel *et al.*, 2012). It has been reported that injection of valproic acid *in ovo* caused axial endo-skeletal anomalies (Whitsel *et al.*, 2002).

Ginger is the rhizome of the plant *Zingiber officinale* Roscoe, member of the family of *Zingiberaceae* (Wattanathorn *et al.*, 2011; Johari *et al.*, 2013). Ginger has a long history of medicinal use in traditional medicine for conditions such as headaches, toothache, colds, improvement of circulation of the limbs and lowering blood cholesterol (Zahedi *et al.*, 2012). Furthermore, ginger has anti-cancer, anti-inflammatory properties as well as anti-nausea/vomiting properties (Young *et al.*, 2005).

Saeid (2012) mentioned that a lot of active materials exists in the crushed ginger and celery seeds which improved the hatching rate, since the ginger contains components like flavonoids, limoin and vitamins E and C (Shalaby and Zorba. 2010), as well as a great amount of feed elements, minerals and vitamins that are considered important to the growth of the embryos (Abbas *et al.*, 2014). Ebrahimnezhad *et al.* (2014) suggested that ginger may improve growth performance in broiler chickens. The aim of the current study was therefore to investigate the possible toxic

side effects of *in ovo* injection of GBP during the embryonic development of chick embryos in terms of morphological and endo-skeletal development. Meanwhile, we aimed to examine the possible ameliorative role of ginger against the induced GBP toxicity in chick embryos.

## 2. Materials and Methods

Principles of animal care and use were carefully followed during conducting the present study according to the guide for the care and use of laboratory animals approved by Faculty of Science, Menoufia University, Egypt (Approval No. MNSE2180). Normal fertilized hen eggs (*Gallus domesticus*) were obtained from a local breeder at Shebeen El-Koom, Menoufia governorate. Before incubation at 37°C in an artificial incubator, eggs were cleaned with distilled water followed by 70% ethanol, weighed ( $50 \pm 5$  g) and then labeled on the outer shell. To ensure the relevant humidity (65%), an open 1-liter container filled with distilled water was placed at the bottom of the incubator. The eggs were put horizontally and turned over, at least, three times a day. At the 6<sup>th</sup> day of incubation, the eggs were divided into five groups 15 eggs each.

- 1- Group A was not subjected to any injection (Control group).
- 2- Group B was injected *in ovo* with 0.2 ml of distilled water (Sham group).
- 3- Group C was injected *in ovo* with 0.2 ml of GBP at a dose of 5.4 mg/egg equivalent to the therapeutic human dose 1800 mg/kg. The single dose was calculated according to Guvenc *et al.* (2013).
- 4- Group D was administered 0.2 ml of ginger extract at a dose of 4.5 mg/egg (Hajati *et al.*, 2014).

5- Group E was given 0.2 ml of 1:1 mixture of GBP (5.4 mg/egg) and ginger extract (4.5 mg/egg).

At the 6<sup>th</sup> day of incubation, a hole was made on the blunt end of the egg with a sharp and thin needle under septic conditions. Using a sterile syringe, 0.2 ml of fluid was injected into the air sac. The holes were carefully sealed with molten paraffin wax after the single dose injection in all experimental groups. The egg was returned to the incubator again for further development.

### **Embryo collection**

All eggs were opened on the 20<sup>th</sup> day of incubation. The embryos were carefully freed from the eggshell. After careful morphological investigation, the body weight and length of the embryos were recorded and then the embryos were photographed. The embryos were eviscerated and kept in 10 % formalin for detection of endo-skeletal malformations.

### **GBP administration**

GBP, with the trade name Gaptin, (Delta Pharma Company, Egypt) was employed for the study. Gaptin capsules of 300 mg/kg concentration were used. The capsules were emptied, and the powder was weighed and dissolved in 1 ml distilled water and *in ovo* injected (0.2 ml) as a single dose (5.4 mg/egg) using insulin syringe on the sixth day of incubation.

### **3. Water extraction of ginger**

Fresh rhizomes of ginger (*Zingiber officinale*) were purchased from a local market at Shebeen El-Koom, Menoufiya, Egypt. They were shade dried at room temperature and then crushed to powder. 125 g of the powder were macerated in 1000 ml of distilled water for 12 h at room temperature and filtered through a 5 µm filter paper to obtain the final aqueous extract.

Accordingly, concentration of the obtained extract was 24 mg/ml and equal to 120 mg/kg (Kamtchouing *et al.*, 2002). Ginger extract was *in ovo* injected as a single dose (4.5 mg/egg) solely or along with GBP on the sixth day of incubation.

### **Investigated parameters:**

#### **Morphometric parameters**

The weight (g) and crown-rump length of chick embryos of different groups was recorded.

#### **Endo-skeletal investigation**

For endo-skeletal preparations, double staining transparency technique was applied using the chondrogenic indicator Alcian blue and the osteogenic indicator Alizarin red S for staining cartilage and bone, respectively. This has been achieved following the method modified by Badawy *et al.* (2012) and originally introduced by Cortés-Delgado *et al.* (2009). Specimens were then examined in glycerol at low resolution under Heerbrugg M3C dissection microscope and at high resolution using a Leitz Laborlux S light microscope. Photographs of the representative samples were taken using Sony digital camera. Lengths of different long bones were measured.

#### **Data evaluation and statistical analysis**

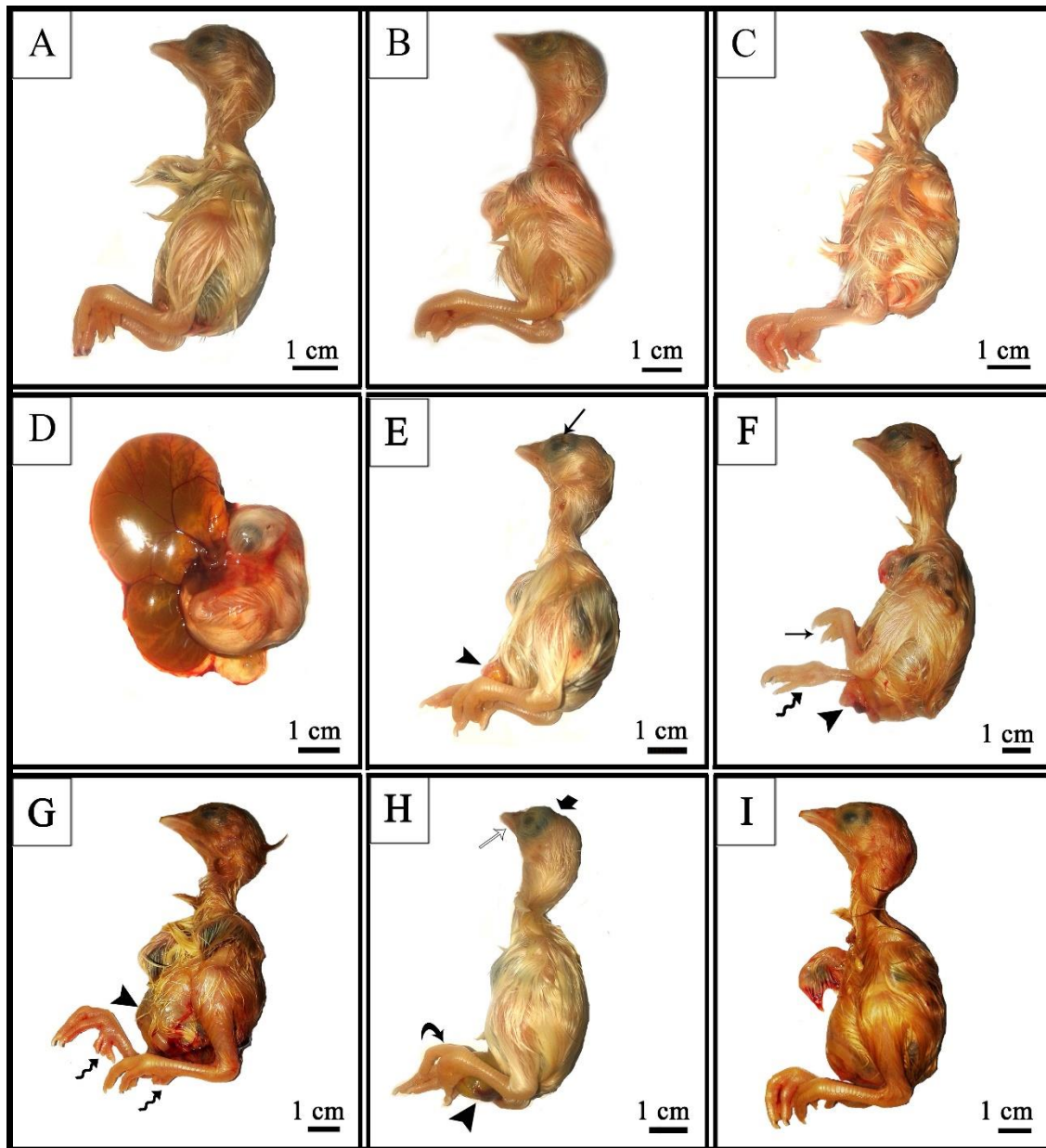
All data sets were expressed as mean  $\pm$  standard error of the mean (SEM). The data were analyzed statistically using one-way ANOVA with Tukey's post-hoc test for multiple comparisons using IBM SPSS statistics software for Windows, Version 22 (IBM Corp., Armonk, NY, USA). Differences were considered insignificant whenever  $P > 0.05$ . The significances of the obtained data were classified into two categories, i.e.  $P < 0.001$ , and  $P < 0.05$  according to the obtained P values.

## 4. Results

### Morphological and morphometric investigations

The body parts of the embryo aged 20 days were covered with down feathers, the beaks were enlarged, hard and covered by a horny layer. The nostrils were narrow slits, and the external auditory apertures were in the form of narrow spherical openings with elevated edges and were located at right angle of a distance about 2 mm behind the eyes. The eyes were of a relatively larger size comparable to head size and had well developed eyelids. The wing and leg of the embryos showed the normal parts, and the digits were made of distinct phalanges ended with small claws. All embryos of control, sham and ginger injected groups showed this normal structure (Fig. 1 A-C), however there was low incidence of omphalocele and limb deformities (20%, 20% and 25% for the three groups, respectively) (Table 1).

On the other hand, chick embryos injected with GBP showed significant growth retardation and high incidence of omphalocele (93.8% Fig. 1 D, Table 1) as well as limb deformities which included bifurcation of first toe, clinodactyly and flexed limbs (56.3%, Fig. 1 E-H, Table 1). Short beak was evident in 37.5% of embryos from the drug group (Fig. 1 H). Twenty-five percent of embryos showed subcutaneous hemorrhage (Fig. 1 E) and exencephaly (Fig. 1 H, Table 1). Co-administration of GBP followed by ginger resulted in marked improvement in the shape of chick embryos as well as decrease in the degree of omphalocele and limb deformities (33.3%, Fig. 1 I, Table 1).



**Figure (1):** Photo-macrographs of 20-day-old representative chick embryos from control (A), sham (B), ginger (C), GBP (D-H) and GBP + ginger (I) groups. A, B & C- normal morphology. D- growth retardation with omphalocele. E- subcutaneous hemorrhage around the eye region (black arrow) and omphalocele (arrow head). F- omphalocele (arrow head) with flexed limb (wavy arrow) and clinodactyly (arrow). G- omphalocele (arrow head) with bifurcated first toe (wavy arrow). H- short beak (white arrow), omphalocele (arrow head) as well as skull defects (thick arrow). I- marked improvement in the shape and length compared with the GBP group.



**Table (1):** Percentage of chick embryos with morphological abnormalities (%) recorded at the end of experimentation, *i.e.* the 20<sup>th</sup> day of incubation in different groups.

Malformation	Groups				
	Control n=15	Sham n=15	Ginger n=12	GBP n=16	GBP + Ginger n=12
Omphalocele	(3) 20%	(3) 20%	(3) 25%	(15) 93.8%	(4) 33.3%
Limb deformities	(3) 20%	(3) 20%	(3) 25%	(9) 56.3%	(4) 33.3%
Short beak	0%	0%	0%	(6) 37.5%	0%
Subcutaneous hemorrhage	0%	0%	0%	(4) 25%	0%
Exencephaly	0%	0%	0%	(4) 25%	0%

The percentage of every abnormality was calculated according to each group.

## Morphometric analysis

### Crown-rump length

Table (2) shows that the chick embryos of control, sham and ginger injected groups had quite similar values for the crown-rump length ( $22.06 \pm 1.35$ ;  $20.04 \pm 0.58$ ;  $20.78 \pm 0.47$  for the three groups, respectively). On the other hand, the length of embryos injected with GBP displayed a highly significant shortening compared with control group ( $14.20 \pm 0.68$ ;  $22.06 \pm 1.35$  for the two groups, respectively). Meanwhile, embryos injected with GBP and ginger displayed a highly significant increase in the length compared with GBP alone ( $20.01 \pm 0.56$ ;  $14.20 \pm 0.68$  for GBP +

ginger and GBP groups, respectively). This in return, led to insignificant difference between GBP + ginger and control groups.

### **Body weight**

Table (2) illustrates the changes in body weight of chick embryos aged 20 days in the different groups. The embryos from the control, sham and ginger injected groups had very close values ( $40.17 \pm 1.05$ ;  $39.40 \pm 1.33$ ;  $39.97 \pm 1.52$  for the three groups, respectively). There was a highly significant decrease in the body weight of GBP injected group ( $29.86 \pm 0.57$ ). Injection of ginger and GBP led to a marked amelioration of body weight compared with GBP group ( $37.42 \pm 0.95$ ;  $29.86 \pm 0.57$  for GBP + ginger and GBP groups, respectively). This significant amelioration of body weight led to insignificant difference towards the control group.

**Table (2):** Crown-rump length, body and brain weights of chick embryos aged 20 days in different groups.

Groups	Chick Embryos Growth Parameters	
	Length	Weight
Control	$22.06 \pm 1.35$	$40.17 \pm 1.05$
Sham	$20.04 \pm 0.58$	$39.40 \pm 1.33$
Ginger	$20.78 \pm 0.47$	$39.97 \pm 1.52$
GBP	$14.20 \pm 0.68^{**}$	$29.86 \pm 0.57^{**}$
GBP + Ginger	$20.01 \pm 0.56^{##}$	$37.42 \pm 0.95^{##}$

Data are represented as mean  $\pm$  SEM.

\*\* P <0.001 compared with the control group.

## P <0.001 compared with GBP group. n=6.

## **Endo-skeletal investigation**

### **Control group**

Examining the double stained endo-skeletal system of the 20-day-old control chick embryos revealed that the parts of the skull with complete ossification were represented by the premaxilla, maxilla, nasal, lachrymal, frontal, parietal, palatine, mandible, pterygoid, supraoccipital, basioccipital, exoccipital and quadrate bones and were stained heavy red exhibiting a large degree of ossification. The squamosal, interorbital, otic and nasal capsules were less ossified. The bones of the upper jaw were slightly longer than those of the lower jaw (Fig. 2 A&B).

The vertebral column of the control group embryos had a normal ventral curvature without any lateral flexion. It was divided into 14 cervical, 7 thoracic, 7 lumbar, 7 sacral and 7 free caudal vertebrae followed by the pygostyle. The cervical vertebrae showed partial ossification at their centra and their transverse processes which stained heavy red. In the thorax, the first two and seventh thoracic vertebrae were free, while the vertebrae 3-6 were fused. The centra of the thoracic vertebrae were mostly ossified and fused with the middle parts of the vertebral portions of the ribs, the central portions of the ilium and ischium of the pelvic girdle, lumbar and sacral regions forming the synsacrum. The lumbar regions consisted of seven fused vertebrae, while the external margins of the sacral transverse processes were fused forming a complete oval ring. A rostra-caudal gradient was seen with the cervical vertebrae almost completely red, while the lower lumbar and

sacral vertebrae still contained extensive blue staining regions and the lowest fused four to five vertebrae stained only blue. Intervertebral discs, caudal vertebrae and pygostyle were mostly cartilaginous in nature and therefore stained blue. In some cases, however, the first two-three caudal vertebrae were partially ossified (Fig. 2 A&B).

The sternum was enlarged forming the carina and it was fully cartilaginous (Fig. 2 A). At the level of the ribs, the sternal portions of the ribs connected to the sternum were cartilaginous with no evident signs of ossification (Fig. 2 A), while those articulating with the thoracic vertebrae were mostly ossified (Fig. 2 B). The vertebral ribs were well separated from each other. The scapula had a slightly curved shape and its caudal end did not reach the ilium. The main body of scapula and coracoid stained heavy red, while their ends were fully cartilaginous (Fig. 2 B). The ischium and ilium were mostly ossified and stained heavy red, while the pubis was mostly cartilaginous in nature, except in its middle part which was ossified and slightly curved (Fig. 2 A).

The joints and epiphyses of the long bones were completely cartilaginous. The long bones including humerus, radius and ulna, femur and tibiotarsus, carpo-metacarpus and tarso-metatarsus were completely ossified except in the epiphyseal regions. Most of the fore limb and all the hind limb phalanges were completely ossified (Fig. 2 A&B).

### **Sham and ginger groups**

There was no significant difference in the endo-skeletal structure of chick embryos of the sham and ginger groups compared with those of the control one, although, 10% of embryos exhibited hind limb malformation in the form of clinodactyly in both groups, and pubic

malformation in the ginger group (Table 3). The skull, vertebral column, sternum, ribs, and limbs showed normal endo-skeletal structure like that of the control group (Fig. 2 C-F).

### **GBP group**

Chick embryos injected with a single dose of GBP on the 6<sup>th</sup> day of incubation had various endo-skeletal malformations (Table 3; Fig. 3 A-F). Defects of the axial endoskeleton included those of the skull cap, beak, vertebrae, sternum and ribs. Generally, the ossification pattern of chick embryos injected with GBP on the 6<sup>th</sup> day of incubation was quite similar to that of the control group, however, there were cases of severe delayed ossification where only few bones stained red (Fig. 3 A).

Malformation of skull and beak constituted 40% of the endo-skeletal malformations. The most evident skull defects were delayed ossification in some parts of the skull (Fig. 3 A), in addition to loss of parts of some bones, especially frontal and parietal ones (Fig. 3 B-E). The main endo-skeletal abnormality of the jaws was shortening of the jaws, especially the premaxilla in the upper jaw (Fig. 3 A&C).

Vertebral defects were the second most endo-skeletal abnormality noticed in chick embryos of this group with incidence of 80% (Table 3). These were divided into cervical fusion between atlas and axis vertebrae (62.5%, Fig. 3 B-D), as well as posterior curvature of cervical vertebrae or kyphosis (37.5%, Fig. 3 B). Scoliosis or lateral curvature of spine had the least vertebral column endo-skeletal defect incidence with only 25 % of chick embryos suffered from this anomaly (Fig. 3 B). Endo-skeletal alterations of caudal vertebrae were divided into caudal regression syndrome,

where embryos suffered from reduction in size of caudal part of endoskeleton or complete absence of tail (87.5 %, Fig. 3 E&F) in addition to kinked tails and pygostyle (50%, Fig. 3 D&G).

Rib anomalies constituted 70% of all the endo-skeletal anomalies in the chick embryos (Table 3) and came in the third place among the induced endo-skeletal defects of this group with 42.7% of chick embryos having separated ribs, 85.7% of embryos suffering from incomplete ossification of the vertebral portion of the ribs and 14.3% with extra ribs (Table 3; Fig. 3 B, C, D & F). Only 20% of embryos had malformed sternum and thus it constituted the least incidence of endo-skeletal anomalies (Table 3; Fig. 3 F).

Amongst the defects of the appendicular endoskeleton came the scapula with incidence of 40% (Table 3) in the form of shortening of the scapula, especially the right one accompanied with a malformed cartilaginous caudal end. On the other hand, the pubis was markedly malformed (80 %, Table 3) and appeared sometimes C-shaped or L-shaped and with delayed ossification. Almost all chick embryos had limb malformations and it was the most common endo-skeletal anomaly observed with incidence of 100% in embryos of GBP group (Table 3). The majority of limb malformation was higher in the hind limb than the forelimb (100% and 40%, respectively). Clinodactyly was the most common anomaly of limb endo-skeletal malformations as well as furcation of the first toe and finger (Fig. 3 A-G). Short femur was also evident (Fig. 3 C).

### **GBP + ginger Group**

Injection of GBP and ginger in the 6<sup>th</sup> day of incubation *in ovo* resulted in an evident decrease in the endo-skeletal malformations compared with the GBP group (Table 3; Fig. 3 H&I). Skull anomalies were reduced to only 10% compared with the GBP group and included slight


delay in the ossification pattern of skull cap (Table 3). Vertebral column deformities constituted 33.3% with 100% of chick embryos suffering from caudal regression syndrome and 33.3% of the embryos had cervical kyphosis and fusion between atlas and axis vertebrae as well as kinked tail (Table 3). Malformation of the ribs were decreased to 10% and were in the form of extra ribs (Table 3; Fig. 3 H). There were no signs of endo-skeletal malformation neither in the sternum nor in the scapula, however, 20% of chick embryos of this group had abnormal pubis with delayed ossification pattern (Table 3; Fig. 3 H). Limb malformations constituted 20% of all the induced endo-skeletal anomalies which occurred mainly in the hind limb (Table 3). Clinodactyly and furcation of the first toe were the main endo-skeletal abnormality in the chick embryos of this group (Fig. 3 H). The ossification pattern was very close to that of the control group with few exceptions in the pubis bones of some embryos (Fig. 3 H).

Investigation of the pattern of ossification centers of long bones revealed variations in their lengths among different groups which were demonstrated in Table (4). As for forelimb, the lengths of the ossification centers in humerus, radius, ulna and carpo-metacarpus were measured. The humerus showed insignificant difference among the control, sham and ginger groups ( $1.21 \pm 0.023$  cm,  $1.16 \pm 0.018$  cm and  $1.11 \pm 0.032$  cm, respectively), while GBP injected group showed highly significant decrease compared with control ( $0.73 \pm 0.025$  cm). Co-administration of ginger and GBP resulted in low significant decrease and high significant increase in the length of ossification centers in humerus when compared with the control and GBP groups, respectively and about  $0.94 \pm 0.017$  cm of the bone was ossified. The same trend was seen in radius ( $0.90 \pm 0.013$  cm,  $0.88 \pm 0.029$  cm,  $0.86 \pm 0.026$  cm,  $0.62 \pm 0.030$  cm and  $0.79 \pm 0.016$  cm for control, sham, ginger, GBP and GBP+ ginger, respectively). As for ulna and carpo-metacarpus, there was no significant


difference among the control, sham and ginger groups, ulna ( $0.95\pm 0.013$  cm,  $0.88\pm 0.018$  cm and  $0.85\pm 0.014$  cm, respectively), carpo-metacarpus ( $0.70\pm 0.017$  cm,  $0.65\pm 0.016$  cm,  $0.62\pm 0.015$  cm, respectively). The lengths showed low significant decrease in both bones in the GBP group when compared with control group ( $0.71\pm 0.027$  cm and  $0.48\pm 0.017$  cm, for ulna and carpo-metacarpus, respectively). Meanwhile, co-administration of ginger with GBP resulted in no (ulna) and low (carpo-metacarpus) significant differences when compared with control, while the case was reversed when compared with GBP group ( $0.84\pm 0.027$  cm and  $0.55\pm 0.017$  cm for ulna and carpo-metacarpus, respectively).

As for hind limb, the lengths of ossification centers of three long bones, femur, tibiotarsus and tarso-metatarsus, were recorded. Insignificant difference was found among the control, sham and ginger groups in the lengths of the three bones, femur ( $2.18\pm 0.038$  cm,  $2.13\pm 0.032$  cm and  $2.07\pm 0.028$  cm), tibiotarsus ( $2.48\pm 0.049$  cm,  $2.42\pm 0.033$  cm and  $2.39\pm 0.070$  cm) and tarso-metatarsus ( $1.77\pm 0.015$  cm,  $1.76\pm 0.026$  cm and  $1.71\pm 0.018$  cm). On the other hand, GBP injected group had the lowest values in the lengths of the three bones and showed highly significant decrease, in case of femur and tibiotarsus, and low significant decrease, in case of tarso-metatarsus, when compared with control group ( $1.25\pm 0.88$  cm,  $1.82\pm 0.031$  cm and  $1.42\pm 0.056$  cm for the three bones). In the combined ginger and GBP group, the femur length showed highly significant decrease when compared with the control group and insignificant difference when compared with GBP group ( $1.27\pm 0.78$  cm), while in case of tibiotarsus and tarso-metatarsus, there was low significant decrease and low significant increase in their lengths when compared with control and GBP groups ( $2.05\pm 0.062$  cm and  $1.57\pm 0.023$  cm for the two bones, respectively).





**Figure (2):** Photo-macrographs of ventral (A, C & E) and dorsal (B, D & F) views of the endoskeletal system of 20-day-old chick embryos from control (A&B), sham (C&D) and ginger (E&F) groups double stained with Alizarin red S and Alcian blue showing well-formed endoskeleton with normal ossification of the skull, vertebral column, sternum, ribs and extremities.



**Figure (3):** Photo-macrographs of ventral (A, B, E, F & G) and dorsal (C, D, H & I) views of the endo-skeletal system of 20-day-old chick embryos from GBP (A-F) and GBP + ginger (H&I) double stained with Alizarin red S and Alcian blue. A- Absence of ossification pattern except in some bones of the skull, fore limb, ilium and hind limb. Arrow indicates either furcation of the first toe (A, C, E, G) or clinodactyly (B, D, F, H), while extra digit is indicated by the curved arrow (E). Short beak is indicated by the wavy arrow (A, C). Depression in the calvaria bones is indicated by the thick arrow (B, C, D, E, G), fusion between atlas and axis cervical vertebrae is indicated by \* in (B, C, D), double arrow refers to either cervical kyphosis (B) or unossified pubis (H), arrow head indicates incomplete ossification of rib (B, C, D, F, H). Double thick arrow refers to short femur (C). Kinked tail and pygostyle is indicated by the double wavy arrow (D, G), while caudal regression syndrome is referred by tailed arrow(E, F). I-nearly normal endo-skeletal structure and ossification pattern compared with control group.

**Table (3):** Endo-skeletal abnormalities in the 20-day-old chick embryos of different groups (%).

Endo-skeletal abnormality	Groups				
	Control n= 10	Sham n= 10	Ginger n= 10	GBP n= 10	GBP + Ginger n= 10
<b>Skull and lower jaw abnormalities</b>	0%	0%	0%	(5) 50%	(1) 10%
<b>Vertebral column</b>	0%	0%	0%	(8) 80%	(3) 30%
Fusion of atlas and axis				(5) 62.5%	(1) 33.3%
Cervical kyphosis				(3) 37.5%	(1) 33.3%
Scoliosis				(2) 25%	0%
Caudal regression syndrome				(7) 87.5%	100%
Kinked tail and pygostyle				(4) 50%	0%
<b>Ribs</b>	0%	0%	0%	(7) 70%	(1) 10%
Separated				(3) 42.7%	0%
Incomplete ossification				(6) 85.7%	0%
Extra rib				(1) 14.3%	100%
<b>Sternum</b>	0%	0%	0%	(2) 20%	0%
<b>Scapula</b>	0%	0%	0%	(4) 40%	0%
<b>Pubis</b>	0%	0%	(1) 10%	(8) 80%	(2) 20%
<b>Limb malformations</b>	0%	10%	(1) 10%	(10) 100%	(2) 20%

Fore limb		0%	0%	(4) 40%	0%
Hind limb		100%	100%	100%	100%

The percentage of every abnormality was calculated according to each group.

Table (4): Lengths of the ossified centers of the long bones in 20-day-old chick embryos of different groups.

Groups	Humerus	Radius	Ulna	Carpometacarpus	Femur	Tibiotarsus	Tarso-metatarsus
Control	1.21 ± 0.023	0.90 ± 0.013	0.95 ± 0.013	0.70 ± 0.017	2.18 ± 0.038	2.48 ± 0.049	1.77 ± 0.015
Sham	1.16 ± 0.018	0.88 ± 0.029	0.88 ± 0.018	0.65 ± 0.015	2.13 ± 0.032	2.42 ± 0.033	1.76 ± 0.026
Ginger	1.11 ± 0.032	0.86 ± 0.026	0.85 ± 0.014	0.62 ± 0.016	2.07 ± 0.028	2.39 ± 0.070	1.71 ± 0.018
GBP	0.73 ± 0.025**	0.62 ± 0.030**	0.71 ± 0.027*	0.48 ± 0.017*	1.25 ± 0.88**	1.82 ± 0.031**	1.42 ± 0.056*
GBP+ginger	0.94 ± 0.017*##	0.79 ± 0.016*##	0.84 ± 0.014#	0.55 ± 0.012*	1.27 ± 0.78##	2.05 ± 0.062*#	1.57 ± 0.023*#

Data are represented as mean ± SEM.

\* P<0.05    \*\* p<0.001 compared with the control group.

# P<0.05    ## p<0.001 compared with GBP group.    n=6.

## 5. Discussion

It has been known that administration of higher dosages of AEDs, higher concentrations of these drugs in the blood, and polytherapy are all associated with higher risks for both anatomical and behavioral teratogenesis in the embryo. For some drugs, such as valproate, phenobarbital, phenytoin, and carbamazepine, the risks are widely studied and outcomes for the fetus are more or less clear (Meador *et al.*, 2009). However, there is no sufficient knowledge concerning teratogenic effect of newer AEDs and few studies have assessed their teratogenic risks (Afshar *et al.*, 2009; Prakash *et al.*, 2008). Therefore, the present study was designed to address the potential teratogenic effects of the new AED, GBP on the morphological and endo-skeletal development of chick embryos.

The current study revealed no significant differences in mortality rate of chick embryos among different groups, however, other studies have shown increased mortality rate associated with injection of various AEDs. This could be related to the time of administration as revealed by different studies. Chick embryos exposed to valproic acid *in ovo* in zero day showed increased mortality (Akhtar *et al.*, 2015; Akhtar and Khan, 2016). Reddy *et al.* (2016) studied the effect of carbamazepine and phenytoin in the developing chick embryos and reported that injection of high doses of both drugs on the 5<sup>th</sup> day of incubation induced high mortality rates that reached 100% in a dose dependent fashion.

The present study revealed an evident growth retardation in the form of decreased crown-rump length and body weight of chick embryos following injection of single dose of GBP on the 6<sup>th</sup> day of incubation. These results are in accordance with previous studies investigating the

teratogenicity of other AEDs on chick embryos. Singh and Shah (1989) showed that embryos that survived injection of phenytoin were remarkably reduced in size and weight compared with those of the control group. Decreased length of the body was evident in chick embryos treated with haloperidol (Abd El-Magid and Al-Ghamdi, 2009). Injection of high doses of carbamazepine or phenytoin on the 5<sup>th</sup> day of incubation resulted in severe growth retardation of the chick embryos (Reddy *et al.*, 2016). The reduction of embryonic body weight of chick embryos in the present study could be explained by the obtained higher incidences of inappropriate yolk formation that may cause a decrease in residual yolk composition which is the main energy source for the developing embryo (Mobarak, 2010). Speake *et al.* (1998) stated that yolk supplies more than 90% of the total energy requirements of the embryo by oxidation of yolk lipids. Al-Qudsi and Al-Jahdali (2012) had another explanation for growth retardation of the developing chick embryos which could be attributed to inadequate amounts of blood reached the embryo therefore the amount of nutrients transferred from yolk to embryo was not enough, leading to growth retardation.

Meanwhile, GBP injection also resulted in different morphological alteration in the developing chick embryos in the current study. Morphological abnormalities included high incidence of omphalocele as well as limb deformities in the form of bifurcation of first toe, clinodactyly and flexed limbs, in addition to short beak. Subcutaneous hemorrhage and exencephaly occurred, but in lower incidence. The previous results agree with other studies which ascertain the induced morphological malformation in chick embryos due to AEDs administration. The spectrum of anomalies resulting from injection of phenytoin included beak abnormalities such as protrude, short, broad and crossed beak. On examination of limbs, shortened limbs with torsional and angular deformities were observed. The digits were either hyperextended or flexed

with hypoplastic claws. The wings were grossly reduced in size with reduced development of feathers (Singh and Shah, 1989). A single dose of carbamazepine was injected into the yolk sac of early stages of chick embryos resulted in exencephaly, anophthalmia, ectopia viscera, ectopia cordis, beak anomaly, limb anomaly and edema (Sonoda *et al.*, 1998). Chicken embryos exposed to valproic acid *in ovo* demonstrated similar anomalies including defects in neural tube, limb abnormalities, failure of retraction of yolk sac into the abdominal cavity, eye abnormality, craniofacial, as well as growth delay and increased mortality (Whitsel *et al.*, 2002; Akhtar *et al.*, 2015; Akhtar and Khan, 2016). Beak deformities were noticed in high doses of carbamazepine and phenytoin injection on the 5<sup>th</sup> day of incubation (Reddy *et al.*, 2016). Hemorrhages, hematomas, and edema formation with the use of teratogens might be due to generalized vascular damage and poor utilization of the yolk. The beak and limb defects might be due to the reaction of the drug with cation ionophores which modulate their movement across lipid membranes (Mathur *et al.*, 2013).

The current study showed that *in ovo* injection of GBP as a single dose on the 6<sup>th</sup> day of incubation resulted in increased incidence of various endo-skeletal malformations as well as delayed ossification of some parts of the endoskeleton of chick embryos. Few workers have reported that AEDs induce endo-skeletal anomalies in chick embryos. Whitsel *et al.* (2002) reported abnormalities in axial and limb endo-skeletal structures in chicken embryos treated *in ovo* with valproic acid in embryonic stages varied from 14-16 which were similar to those reported for other species. Thoracic endo-skeletal abnormalities were noted but were much less commonly reported than limb deformities. Phenobarbital treatment was also found to induce endo-skeletal malformations in chick embryos (Yan *et al.*, 2016). Different doses of phenobarbital injected *in*

*ovo* were found to cause a marked defect in the ossification of several cartilage-based structures and defects in endochondral ossification in the vertebral column and in the appendicular endoskeleton at the level of different limb parts. Endo-skeletal abnormalities in chick embryos could be attributed, to some extent, to the timing of applying GBP. It has been suggested that treatment of embryos before 8<sup>th</sup> day of incubation affects the endo-skeletal development as it has been found by Osdoby and Caplan (1981) that mineralization of the long bones in the chick embryo hind limbs begins by day 8 of development. Additionally, the short beaks of some chick embryos of the present study could be explained in the light of Taparia *et al.* (2014) hypothesis who returned beak abnormalities to impairment of chondroitin sulfate, through interference with a NAD-dependent process. The curled toes and flexed digits seen in chick embryos injected with GBP in the present study could be attributed to muscular tension in the feet at the time of toe bones ossification (Rao *et al.*, 1992).

Along with different endo-skeletal defects, the present study showed reduced length of the ossified parts of long bones of fore and hind limbs in chick embryos injected with GBP during the organogenesis period. This was consistent with other studies. Numerous studies suggest that patients with epilepsy treated with AEDs may be at an increased risk for bone disease including changes in bone turnover, osteoporosis, alterations in bone quality, and fracture (Pack, 2008; Carbone *et al.*, 2010). However, there is still very limited understanding of the mechanisms of the effect of AEDs on bone health, as well as on the nature of the bone disease including osteoporosis and osteomalacia (Nowińska *et al.*, 2012). Yan *et al.* (2016) assumed two possibilities to give rise to the shortened length of chick long bones. First is the small cartilage template induced by treatment as it has been proven that the formation of a proper cartilage model is a prerequisite for



normal endochondral ossification (Knudson and Knudson, 2001). The other possible explanation for the shorter long bones is that the process of mineralization was defective due to AED treatment which causes the blockage of calcium channels, and eventually leads to a loss in bone mineral density (Hernández-Díaz and Levin, 2014).

There are limited studies on the effects of ginger on the developing chick embryo. The present study revealed increased weight and length of chick embryos injected with ginger on the 6<sup>th</sup> day of incubation, this was accompanied by ameliorative effect on the morphological gross abnormalities which were evidently decreased to be quite similar to that of the control group. Ginger was found to improve body weight gain in broiler chickens when administered in their diet (Ebrahimnezhad *et al.*, 2014; Singh *et al.*, 2014). Debes and Basyony (2011) investigated the effect of oregano and ginger oils versus formaldehyde fumigation on White Leghorn in terms of hatching and chick performance. They found that embryo mortality was lower in both of oregano and ginger oils groups compared with formaldehyde fumigation groups, in addition, the best chick weight at hatch time was observed in the ginger oil group. Administration of vitamin C, which is a constituent of ginger, and folic acid to chick embryos treated with methylmercury resulted in increased survival rate and decrease in the overall gross malformations (Bekhet *et al.*, 2013).

Changes in prenatal bone health and fetal osteogenesis have been positively correlated with excessively elevated reactive oxygen species (ROS) that may lead to improper skeletal formation (Scifres and Nelson, 2009). The embryonic and fetal development periods are believed to be extremely sensitive to high levels of ROS in part because effective free radical scavenging systems are not yet fully developed (Ornoy, 2007). In the current study, administration of ginger along with

GBP during the organogenesis phase of chick embryonic development was associated with decrease and improvement of endo-skeletal malformation and increase in ossification at various levels in the whole endoskeleton together with improvements in the lengths of long bones of both fore- and hind-limbs towards the control figures. In support of the present results, some studies showed the ability of ginger to increase bone ossification and reduce bone turnover. Wilkinson (2000) found that fetuses exposed to ginger tea were found to have significantly more endo-skeletal, especially sternal, ossification. Weidner and Sigwart (2001) reported that ginger treatment resulted in no endo-skeletal malformations and fetuses were found to have decreases in endo-skeletal alterations, followed by enhanced trends in the number of tail ossification centers. Ginger administration was found to cause improvements in bone microarchitectures and structure and decrease the osteoporotic changes in femur diaphysis and metaphysis caused by cadmium chloride and bilateral ovariectomy in the study of Mustafa *et al.* (2013). The authors explained this ameliorating effect of ginger and improvement in bone structure to be related to the antioxidant characters of ginger, as well as its bone protection against oxidative damage induced by cadmium. All of the above mentioned ameliorative and protective effects of ginger could be attributed to its antioxidant properties (Khaki and Khaki, 2010; Ko and Leung, 2010).

In conclusion, in the light of morphological and endo-skeletal results, the present data confirmed that GBP has adverse effects on the morphology and endoskeleton development of chick embryos. Furthermore, ginger might be a potential candidate agent against experimentally induced GBP induced toxicity via its antioxidant and free radical-scavenging properties. However, further investigations are needed to demonstrate the exact mechanism of ginger on GBP induced toxicity.

## **Ethical Approval**

All the experiments were conducted in compliance with the guide for the care and use of laboratory animals approved by Faculty of Science, Menoufia University, Egypt (Approval No. MNSE2180).

## **Authors Contributions**

Gamal M Badawy: Conceived and designed the experiments; Analyzed and interpreted the data; Contributed reagents, materials, analysis tools or data. Marwa N Atallah: Performed the experiments; Analyzed and interpreted the data; Wrote the paper. Saber A Sakr: Contributed reagents, materials, analysis tools or data.

## **Funding**

The authors declare that no funds, grants, or other support were received during the preparation of this manuscript.

## **Competing Interests**

The authors have no relevant financial or non-financial interests to disclose.

## **Availability of data and material**

All data supporting this work are original and is included within the manuscript. The corresponding author is responsible for supplying any additional data.

## **References**

- Abbas A, Yosif A, Shukur A. (2014). Ali F. Effect of genotypes, storage periods and feed additives in broiler breeder diets on embryonic and hatching indicators and chicks blood parameters. *GJSR.*, 2, 105-10.
- Abd El-Magid B, Al-Ghamdi F. (2009). Changes induces by haloperidol (antidepressant drug) on the developing retina of the chick embryo. *Saudi J Biol Sci.*,16, 85-94.
- Afshar M, Hassanzadeh-Taheri M, Moallem S-A, Tamizi A, Golalipour M. (2009). Teratogenic effects of gabapentin on the skeletal system of Balb/C mice fetuses. *Neurosciences*, 14, 239-44.
- Akhtar L, Khan M. (2006). Frequency of different congenital anomalies in prenatally valproic acid treated chick embryos. *Pak Armed Forces Med J.*, 66, 564-9.
- Akhtar L, Khan M, Minhas L. (2015). The effect of prenatal administration of valproic acid on the survivability and day of hatching of chick embryo. *J Pak Med Assoc.*, 65, 175-8.
- Al-Qudsi F, Al-Jahdali A. (2012). Effect of monosodium glutamate on chick embryo development. *J Am Sci.*, 8, 499-509.

- Badawy G, Sakr S, Atallah M. (2012). Comparative study of the Skeletogenesis of Limb Autopods in the Developing Chick *Gallus domesticus* and Toad *Bufo regularis*. RJPBCS, 3, 966-88.
- Bekhet G, Al-Kahtani M, Abdel-Moneim A. (2013). The protective effects of vitamin C and folic acid against methylmercury teratogenicity in chick embryo. JCAB, 7, 77-84.
- Carbone L, Johnson K, Robbins J, Larson J, Curb J, Watson K, Gass M, Lacroix A. (2010). Antiepileptic drug use, falls, fractures, and BMD in postmenopausal women: findings from the women's health initiative (WHI). J Bone Miner Res., 25, 873-81.
- Cortés-Delgado N, Pérez-Torres J, Hoyos J. (2009). Staining procedure of cartilage and skeleton in adult bats and rodents. Int J Morphol., 27, 1163-7.
- Debes A, Basyony M. (2011). The use of oregano (*Origanum vulgare L*) and ginger (*Zingiber officinale*) oils as alternative hatching egg disinfectant versus formaldehyde fumigation in Leghorn and Matrouh eggs. Egypt Poult Sci., 31, 755-65.
- Ebrahimnezhad Y, Azarakhsh V, Salmanzadeh M. (2014). The effects of ginger root (*Zingiber officiale*) processed to different levels on growth performance, carcass characteristics and blood biochemistry parameters in broiler chickens Bull. Env. Pharmacol. Life Sci., 3, 203-8.
- Etemad L, Afshar M, Mohammadpour A, Vahdati N, Moallem S. (2013). Teratogenic effects of pregabalin in mice. Iran J Basic Med Sci., 16, 1065-70.
- Fadel R, Sequeira R, Abu-Hijleh M, Obeidat M, Salem A. (2012). Effect of prenatal administration of therapeutic doses of topiramate on ossification of ribs and vertebrae in rat fetuses. Rom J Morphol Embryol., 53, 321-7.
- Gissel T, Poulsen C, Vestergaard P. (2007). Adverse effects of antiepileptic drugs on bone mineral density in children. Expert Opin Drug Saf., 6, 267-78.
- Guvenc Y, Dalgic A, Billur D, Karaglu D, Aydin S, Dalioglu E, Ozdol C, Nacar O, Yildirim A, Belen D. (2013). The effects of levetiracetam on neural tube development in the early stage of chick embryos. Turk Neurosurg., 23, 617-22.
- Hajati H, Hassanabadi A, Nassiri-Moghaddam H, Nassiri M. (2014). The effects of in ovo injection of grape seed extract and vitamin C on hatchability, antioxidant activity, yolk sac weight, performance and ileal micro flora of broiler chickens. Res Opin Anim Vet Sci., 4, 633-8.
- Hernández-Díaz S, Levin M. (2014). Alteration of bioelectrically controlled processes in the embryo: a teratogenic mechanism for anticonvulsants. Reprod Toxicol., 47, 111-4.
- Johari H, Delirnasab F, Sharifi E, Hemayat-Khah V, Pourdanesh M, Kargar H, Nikpour M, Yazdani M. (2013). The effects of hydro-alcoholic extract of *Zingiber officinale* on prevention from plumbism in kidney tissue of neonatal rats. ZJRMS, 15, 13-7.
- Kamtchouing P, Mbongue-Fandio G, Dimo T, Jatsa H. (2002). Evaluation of androgenic activity of *Zingiber officinale* and *Pentadiplandra brazzeana* in male rats. Asian J Androl., 4, 299-301.
- Khaki A, Khaki A. (2000). Antioxidant effect of ginger to prevents lead-induced liver tissue apoptosis in rat. J Med Plants Res., 4, 1492-5.

- Knudson C, Knudson W. (2001). Cartilage proteoglycans. *Semin Cell Dev Biol.*, 12, 69-78.
- Ko J, Leung C. (2001). Ginger extract and polaprezinc exert gastroprotective actions by antioxidant and growth factor modulating effects in rats. *J. Gastroenterol Hepatol.*, 25, 1861-8.
- Krasowski M. (2010). Therapeutic drug monitoring of the newer anti-epilepsy medications. *Pharmaceuticals*, 3, 1909-35.
- Mathur P, Taparia N, Nitu K, Shahani L. (2013). Insecticide Marshal® Ec induces teratological changes in the embryos of *Gallus domesticus*. *Int J Pharm Bio Sci.*, 4(B), 267-74.
- Mazziotti G, Canalis E, Giustina A. (2010). Drug-induced osteoporosis: mechanisms and clinical implications. *Am. J. Med.* 123, 877-84.
- Meador K. (2008). Effects of in utero antiepileptic drug exposure. *Epilepsy Curr.*, 8, 143-7.
- Meador K, Penovich P, Baker G, Pennel P, Bromfield E, Pack A, Liporace J, Sam M, Kalayjian L, Thurman D, Moore E, Loring D. (2009). Antiepileptic drug use in women of childbearing age. *Epilepsy Behav.*, 15, 339-43.
- Mobarak Y. (2010). Embryotoxicity and teratogenicity of enrofloxacin on maternally treated chick. *Asian J Dev Biol.*, 2, 1-15.
- Mustafa M, Omayma M, Mahmoud O, Hussein H. (2013). Histological and morphometric effects of CdCl<sub>2</sub> and ginger on osteoporosis induced by bilateral ovariectomy in adult albino rats. *Eur. J Anat.*, 17, 102-14.
- Nasar M. (2014). Gupta R, Subhani T. Teratogenicity of Gabapentin in Mice. *JMSCR.*, 2, 3378-85.
- Nowińska B, Folwarczna J, Dusiło A, Pytlik M, Śliwiński L, Cegięła U, Kaczmarczyk-Sedlak I, Pietryka W, Hanke T, Trzeciak H. (2012). Effects of vigabatrin on the skeletal system of young rats. *Acta Poloniae Pharmaceutica-Drug Research*, 69, 327-34.
- Ochoa J. (2008). Drugs disease and procedure. In: *Antiepileptic drugs*. Medscape reference.
- Ornoy A. (2007). Embryonic oxidative stress as a mechanism of teratogenesis with special emphasis on diabetic embryopathy. *Reprod Toxicol.*, 24, 31-41.
- Osdoby P, Caplan A. (1981). First bone formation in the developing chick limb. *Dev Biol.*, 86, 147-56.
- Pack A. (2008). Bone health in people with epilepsy: Is it impaired and what are the risk factors? *Seizure*, 17, 181-6.
- Perucca E. (2005). Birth defects after prenatal exposure to antiepileptic drugs. *Lancet Neurol.*, 4, 781-6.
- Prakash, Prabhu L, Rai R, Pai M, Yadav S, Madhyastha S, Goel R, Singh G, Nasar M. (2008). Teratogenic effects of the anticonvulsant gabapentin in mice. *Singapore Med J.*, 49, 47-53.
- Rao J, Swamy A, Yamin S, Rao S, Rahaman M. (1992). Teratism induced in the developing chick by RPR-V, an organophosphate. *Food Chem Toxicol.*, 30, 945-51.
- Reddy A, Fulzele R, Ujwalgajbe R, Ambareesha K. (2016). Study on effects of carbamazepine and phenytoin on development of chick embryo. *Int J Res Dev Pharm Life Sci.*, 5, 2388-96.

- Saeid M. (2012). Effect of adding crushed Ginger and Celery seeds and their combinations to the diets on productive performance and some physiological parameters of two strains of Broiler Breeder Chickens and their progeny performance. Ph.D thesis, University of Anbar, Iraq.
- Scifres C, Nelson D. (2009). Intrauterine growth restriction, human placental development and trophoblast cell death. *J Physiol.*, 587, 3453-8.
- Shalaby M, Zorba H. (2010). Protective effect of celery oil, vitamin E and their combination against testicular toxicity in male rats. *Global Veter.*, 5, 122-8.
- Singh M, Shah G. (1989). Teratogenic effects of phenytoin on chick embryos. *Teratology*, 40, 453-8.
- Singh S, Patel J, Bachle D. (2014). A review on *Zingiber officinale*: a natural gift. *Int J Pharm Bio Sci.*, 5, 508-25.
- Sonoda T, Kono K, Itokazu N, Sugimoto T. (1998). Carbamazepine-induced brain weight reduction in chick embryos. *Cong Anom.*, 38, 367-73.
- Speake B, Murray A, Noble R. (1998). Transport and transformation of yolk lipids during development of the avian embryo. *Prog Lipid Res.*, X. 37, 1-32.
- Taparia N, Mathur P, Shahani L. (2014). Toxic action of quinalphos 25% ec (flash), an organophosphate insecticide in induction of skeletal malformations in the embryos of *Gallus domesticus*. *WJPPS.*, 3, 2078- 88.
- Tatum W , Galvez R, (2000). Benbadis S, Carrazana E. New antiepileptic drugs: into the new millennium. *Arch Fam Med.*, 9, 1135-41.
- Tomson T, Battino D. (2012). Teratogenic effects of antiepileptic drugs. *Lancet Neurol.*, 11, 803-13.
- Verrotti A, Coppola G, Parisi P, Mohn A, Chiarelli F. (2010). Bone and calcium metabolism and antiepileptic drugs. *Clin Neurol Neurosurg.*, 112, 1-10.
- Wattanathorn J, Jittiwat J, Tongun T, Muchimapura S, Ingkaninan K. (2011). *Zingiber officinale* mitigates brain damage and improves memory impairment in focal cerebral ischemic rat. *Evid Based Complement Alternat Med.*, 429-505.
- Weidner M, Sigwart K. (2001). Investigation of the teratogenic potential of a *Zingiber officinale* extract in the rat. *Reproductive Toxicology*, 15, 75-80.
- Whitsel A, Johnson C, Forehand C. (2002). An *in ovo* chicken model to study the teratogenic effects of valproic acid. *Teratology*, 66, 153-63.
- Wilkinson J. (2000). Effect of ginger tea on the fetal development of Sprague-Dawley rats. *Reprod Toxicol.*, 14, 507-12.
- Yan Y, Cheng X, Yang R, Li H, Chen J, Ma Z, Wang G, Chuai M, Yang X. (2016). Exposure to excess phenobarbital negatively influences the osteogenesis of chick embryos. *Front Pharmacol.*, 7, 349.
- Young H, Luo Y, Cheng H, Hsieh W. (2005). Analgesic and anti-inflammatory activities of [6]- gingerol. *J Ethnopharmacol.*, 96, 207-10.

Zahedi A, Fathiazad F, Khaki A, Ahmadnejad B. (2012). Protective effect of ginger on gentamicin-induced apoptosis in testis of rats. *Adv Pharm Bull.*, 2, 197-200.