

## **EFFECT OF PROBIOTIC BACTERIA ON AFLATOXINS IN BROILER CHICKENS: GROWTH PERFORMANCE, SERUM PARAMETERS AND HISTOLOGICAL ALTERATIONS**

**El-Afifi, T. M.<sup>1</sup>; Amel A. Abo.Haggar<sup>1</sup>; Assia M.El Sawy<sup>2</sup>; A. F. Abdel - Salam.<sup>1</sup> and Kh. M. El-Meleigy<sup>1</sup>**

<sup>1</sup> Regional Center for Foods and Feeds, Agric. Res. Center, Ministry of Agric., Giza, Egypt.

<sup>2</sup> Animal Health Research Institute, Agric. Res. Center, Ministry of Agric., Giza, Egypt.

### **ABSTRACT**

The main objective of this study was to evaluate aflatoxin (AFs) removal ability of probiotic bacteria. Two hundred and seventy one-day-old (Ross 308) broiler chicks were randomly distributed among nine groups. The dietary treatments were: 1 control; 2&3 artificially contaminated diets with 0.5&1mg of AFs, respectively; 4&5 received oral gavages anaerobic caecal culture (probiotic). 6, 7, 8&9 AFs-contaminated diets plus probiotic feed additive (AFS-PB). The criteria of evaluation included body weight gain (BWG), Feed consumption (FC), and feed conversion ratio (FCR). The toxic effects of aflatoxins were apparently in groups received AFs contaminated diet which showed significantly lower BWG and FC and impaired FCR compared with control diet. Such effects overcome by adding probiotic bacteria to aflatoxin treated groups. On the other hand, AFs treated group showed significant increased in serum liver function enzymes (alanine aminotransferase (ALT), aspartate aminotransferase (AST) ), urea and creatinine levels. The intakes of probiotic bacteria significantly alleviated the elevation of ALT, AST, urea and creatinine levels.

The results indicated the effect of probiotic as a potential protective agent against aflatoxin toxicity to decrease the risk of occurrence of liver and kidney dysfunction and occurrence of cancer and protect against both membrane and DNA damage.

**Keywords:** Probiotic, Broilers, Aflatoxins, Body weight, Feed intake, Feed conversion

### **INTRODUCTION**

Poultry farming is a sub-sector of livestock, which has been developed from backyard chicks rising to commercial farming during the past five decades. Among the agriculture sector, it is considered as one of the most progressive and innovative business ( Rahman *et al.*, 2009). Aflatoxins (AFs) are a group of acutely toxic metabolites produced by toxigenic strains of *Aspergillus flavus* Link, *Aspergillus parasiticus* Speare, and *Aspergillus nomius*. Four principal AFs are produced by those fungi: AFB<sub>1</sub>, AFB<sub>2</sub>, AFG<sub>1</sub>, and AFG<sub>2</sub> ( Feibelman *et al.*, 1998 and Weidenbörner, 2007 ).

In poultry, aflatoxicosis is characterized by acute death, severe hepatic injury, extensive hemorrhages, lowered productivity, and lowered immunity to diseases (Dalvi, 1986). In addition, affected birds retain residues of the aflatoxin in their tissues (Chen *et al.*, 1984). These residues are highest in the liver, gizzard and kidney, but there exists a large individual bird variation in the amount of residues retained and in the duration of time

required for their total clearance (Wolzak *et al.*, 1986). The determination of these residues is necessary for the diagnosis of aflatoxicosis in poultry, in quality control of poultry products.

Beneficial probiotic-microorganisms species belonging to *Lactobacillus*, *Streptococcus*, *Bacillus*, *Enterococcus*, *Aspergillus*, *Candida*, and *Saccharomyces* have been reported to enhance the beneficial intestinal microflora and broiler performance in some studies (Fritts *et al.*, 2000). Some probiotic microorganisms may be reduced or eliminated by the low pH in the gizzard, and thus have little effect in the lower intestinal tract where pathogens pose problems.

Feed additives are added either singly or in combination to basic feed, usually in small quantities as premixes. These are called as non-nutrients feed additives. Probiotic are one of the feed additives; which are the live culture of useful micro-organisms (Rahman *et al.*, 2009).

The probiotics adding protect against food mutagens such as heterocyclic amines, nitroso-compounds and aflatoxins, Certain strains from lactic acid bacteria (LAB) have been reported to adsorb aflatoxins B1, B2, G1, G2, M1, M2 and Zearalenone from liquid media, milk and from the intestine forming a stable complex. The adsorption is a physical process, bacterial cell wall binds the toxin with non – covalent weak bonds accompanied with some electrostatic attraction through lactinine like protein, polysaccharides and peptidoglycan (Gratz *et al.*, 2005).

The poultry industry is continuously searching for additives to improve feed efficiency and animal health; among these compounds probiotics. The probiotic contains micro-organisms like *Saccharomyces cerevisiae*, *Lactobacillus acidophilus*, *Bacillus subtilis* and *Aspergillus oryzae* (Tránsito *et al.*, 2011). These micro-organisms have the ability to secrete energy nutrients hydrolyzing enzymes, such as amylase, protease and lipase in the gastro-intestinal tract. According to the manufacturer claims, these enzymes have the capability to synergize with the endogenous enzymes to enhance their catalytic activities for maximizing the digestion rate of dietary energy nutrients, which in turn improve the growth rate of the chicks as compared to the chicks fed the diets containing no probiotic. Accordingly, the aim of the current study was to evaluate aflatoxins (AFS) removal ability of probiotic bacteria.

## **MATERIALS AND METHODS**

### **Birds :**

This experiment was carried out at the poultry house of the Regional Center for Food and Feed, Egypt Total number of two hundreds and seventy one-day-old Ross 308 broiler chicks were obtained from a commercial farm (El-Wadee). The trial was carried out at a poultry house in Nubaria, Regional Center for Food and Feed, Alexandria, Egypt. The chicks were randomly distributed among nine treated groups of five replicates each (6 chicks per replicate), in a washed fumigated batteries. The temperature was controlled,

feed, water and light were provided for 24 hours. Birds were vaccinated against New Castle, AI and Gambaro diseases.

**Diets, formulation and composition:**

The experimental diets were formulated to cover the chick requirements as recommended by the management guide data (Ross 308). Table 1 showed the formulation and calculated nutrient composition of the experimental diets. The basal starter (1 to 14 days of age) diet was formulated to contain 23% CP, and 3060Kcal ME/Kg, grower (15 to 28 days of age) diet was formulated to contain 22% CP and 3175 Kcal ME/Kg and the finisher diet (29 to 42 days of age) contained 20% CP and 3200 Kcal ME/Kg. Calcium and available phosphorus were adjusted using di-calcium phosphate and limestone. Vitamins and trace minerals were added to cover broiler's requirements.

**Table 1: Ingredients and nutrient composition of the control experimental diet (%).**

<b>Ingredients</b>	<b>Starter</b>	<b>Grower</b>	<b>Finisher</b>
Yellow corn	55.81	55.98	63.0
Soybean meal (45.7% )	30.0	29.0	22.0
Corn gluten meal (60.5%)	7.50	6.75	8.00
Vegetable oil	2.625	4.335	3.275
Dicalcium phosphate	1.74	1.93	1.78
Limestone	0.82	0.55	0.56
Vit. & Min premix <sup>1</sup>	0.40	0.40	0.40
Salt	0.40	0.40	0.40
L-Lysine HCl	0.42	0.39	0.37
DL-Methionine	0.21	0.19	0.14
Choline chloride	0.075	0.075	0.075
Total	100	100	100
<b>Calculated composition<sup>2</sup></b>			
Crude protein %	23.20	22.30	20.30
ME (Kcal/Kg)	3065.3	3179.5	3208.6
Lysine %	1.36	1.30	1.13
Methionine %	0.61	0.57	0.50
Methionine + Cystine %	0.98	0.94	0.85
Calcium %	0.96	0.90	0.85
Available P %	0.46	0.48	0.46

1) Vitamin- mineral mixture supplied per Kg of diet: Vit. (A), 1200 I.U., Vit. (D<sub>3</sub>), 2000 I.U., Vit. (E), 10mg ; Vit. (K<sub>3</sub> ), 2mg; Vit (B<sub>1</sub>), 1mg; Vit. (B<sub>2</sub>), 5mg; Vit. (B<sub>6</sub>), 1.5mg; Vit. (B<sub>12</sub>) 10µg; Biotin, 50µg; Pantothenic acid, 10mg; Niacin, 30mg; Folic acid, 1mg; Manganese, 60mg; Zinc, 50mg; Iron, 30mg; Copper, 10mg; Iodine, 1mg; Selenium, 0.1mg; and Cobalt, 0.1mg.

2) Calculated based on feed composition Tables of NRC (1994)

Table 2 shows that control group was fed the basal diet (G1), while, the other experimental groups (G2, G6, and G7) were provided with low dose of AFs contaminated diet (0.5 mg/Kg). Groups (G3, G8, and G9) were received high dose of AFs contaminated diet (1.0 mg/Kg). Oral gavage with 5×10<sup>10</sup> cfu/ml of self developed undefined anaerobic culture/chick administrated at day 3 post-hatch (G 4). AFs with doses (0.5mg, and 1mg/Kg) were provided to groups (G6 and G8) with anaerobic caecal culture on the

day of hatch only. Undefined anaerobic culture/chick administrated at day 3 post-hatch and 15 day of age (G5). Groups (G7 and G9) were fed on AFs doses (0.5mg and 1mg/Kg) respectively and treated twice with anaerobic caecal culture on the day of hatch and 15 day of age. Live body weight gain and feed conversion ratio were calculated.

**Table 2: Experimental treatments.**

groups	Treatment
G <sub>1</sub>	Control (-) fed on AFT free diet.
G <sub>2</sub>	Control (+) fed on low dose of AFs contaminated diet (0.5 mg/Kg).
G <sub>3</sub>	Control (+) fed on high dose of AFs contaminated diet(1.0mg/Kg).
G <sub>4</sub>	Control (-) treated once with anaerobic caecal culture on the day 3 of hatch only.
G <sub>5</sub>	Control (-) treated twice with anaerobic caecal culture on the day 3 of hatch and 15 day of age.
G <sub>6</sub>	Fed on low dose of AFs and treated once with anaerobic caecal culture on the day of hatch only.
G <sub>7</sub>	Fed on low dose of AFs and treated twice with anaerobic caecal culture on the day of hatch and 15 day of age.
G <sub>8</sub>	Fed on high dose of AFs and treated once with anaerobic caecal culture on the day of hatch only.
G <sub>9</sub>	Fed on high dose of AFs and treated twice with anaerobic caecal culture on the day of hatch and 15 day of age.

**Aflatoxin production and assessment:**

Aflatoxin production was carried out according to Davis *et al.* (1966) using liquid yeast medium and *Aspergillus flavus* strain (NRRL 3145). The media which contain detectable amount of aflatoxin was mixed well with the basal diet to get the aflatoxin - contaminated diet.

The total aflatoxin content in liquid medium, diet, and tissues was determined according to Roos *et al.* (1997) and AOAC (2006) method using monoclonal antibody columns for total aflatoxins (VICAM Science Technology, Watertown, MA, USA). Aflatoxin identification was performed by a modification of the HPLC-AFLATEST procedure Agilent 1200 Series USA. HPLC equipment with two pumps, column C18, Lichrospher 100 RP-18, (5µm×25cm) was used. The mobile phase consisted of water: methanol: acetonitrile (54:29:17, v/v/v) at flow rate of 1ml/min. The excitation and emission wavelengths for all aflatoxins were 362 and 460nm (Fluorescence detector), respectively

**Preparation of anaerobic inoculums:**

The caecal contents from three adult broilers were obtained after slaughtering the birds, mixed and immediately transferred into an anaerobic chamber (Cox laboratory products, Ann Arbor, Michigan). This material was

mixed with five parts of sterile glycerin, and 0.2ml amounts of the suspension then was placed in test tubes and stored at -70°C until use. Before inoculation, 200ml of liver veal lactose (LVL) broth (10g/liter of tryptose, 5g/liter of NaCl, 2.4g/liter of beef extract, 5g/liter of yeast extract, 0.4g/ liter of cystine hydrochloride, 25g/liter of lactose and 0.6g/liter of agar with a final pH of 6.67) was inoculated with a loopfull from the anaerobic inoculums and incubated anaerobically for 24hr, after which plate count was done using LVL ager (the same as LVL broth with the addition of 1.5% agar). The inoculums contained about  $10^{10}$  cfu/ml (Bailey *et al*, 1988).

Detection of *Salmonella* in the caecal content used in the preparation of anaerobic culture: Caecal sample which was used in the preparation of anaerobic culture was examined to ensure its freedomness from *Salmonella* using peptone water as preenrichment broth selective broth *Salmonella*. *Shigella* (S.S) ager as plating medium, biochemical test for identification (NMKL 1999).

#### **Haematological and biochemical examination**

At the end of the experiment, blood samples were collected from three birds of experimental group via wing vein puncture. Serum was separated and stored at -20°C for analysis for measuring the activities of the serum aspartate aminotransferase (AST), and alanine aminotransferase (ALT), while uric acid, and creatinine using commercial kits from Diamond Diagnostics Company, Egypt.

#### **Histopathological techniques:**

Samples of different internal organs of the experimental birds were table for histopathological examination were fixed in 10% formal saline for 2 days, washed in tap water, dehydrated in ascending grades of ethyl alcohol and finally cleared with xylene and embeded in paraffin wax. The paraffin blocks were five – micron cutted and stained by haematoxylin and eosin as described by (Pearse, 1968).

#### **Statistical analysis**

The data obtained were subjected to a one way analysis of variance using the linear model (GLM) of SAS (1990). Means were compared using Duncan's new multiple range test ( $P < 0.05$ ) (Duncan, 1955).

## **RESULTS AND DISCUSSION**

Data presented in Table 3 show that there were no significant differences in body weight gain (BWG), final body weight, feed consumption (FC), and feed conversion ratio (FCR) in all bird groups at starter period. These results are in coincide with Bansal *et al.* (2011) who found that probiotic in diet did not show significant effect on two weeks body weight, also similar findings were observed on feed efficiency.

**Table 3: Effect of aflatoxins contaminated diets and probiotic dosage on broiler chickens performance (at starter period, 0-14 days of age) of different groups (Means  $\pm$ SD).**

Treatments	Item			
	Final body Weight (g)	Body weight gain (g)	Feed consumption (g)	Feed conversion ratio (g feed/g gain)
G1	261 $\pm$ 21	221 $\pm$ 21	272 $\pm$ 4	1.23 $\pm$ 0.11
G2	257 $\pm$ 41	217 $\pm$ 41	265 $\pm$ 15	1.22 $\pm$ 0.17
G3	245 $\pm$ 12	205 $\pm$ 12	257 $\pm$ 10	1.25 $\pm$ 0.08
G4	262 $\pm$ 18	222 $\pm$ 18	265 $\pm$ 16	1.19 $\pm$ 0.10
G5	263 $\pm$ 12	223 $\pm$ 12	262 $\pm$ 13	1.17 $\pm$ 0.06
G6	259 $\pm$ 21	219 $\pm$ 21	271 $\pm$ 16	1.24 $\pm$ 0.14
G7	259 $\pm$ 16	219 $\pm$ 16	268 $\pm$ 10	1.23 $\pm$ 0.07
G8	257 $\pm$ 21	217 $\pm$ 21	269 $\pm$ 6	1.24 $\pm$ 0.11
G9	247 $\pm$ 24	207 $\pm$ 23	263 $\pm$ 14	1.27 $\pm$ 0.09

a: Means within a column with common superscript are not significantly different ( $P < 0.05$ ).

The toxic effects of aflatoxins were apparent in grower, finisher and overall periods (Tables 4,5,6). Groups G2&G3 received low and high dose of AFs contaminated diet, respectively, showed significantly lower BWG& FC ( $P < 0.05$ ) compared with control diet which may be due to the loss of animals appetite caused by aflatoxin. Similar results were obtained by Parlat *et al.* (1999) who found that BWG and FC were decreased significantly by AFB<sub>1</sub> treatment compared with control. In addition, BWG in the groups G5&G6 received probiotic bacteria was significantly ( $P < 0.05$ ) higher compared with negative control (G2 and G3) and FC and FCR were around the negative control. The changes in BWG, FC and FCR were significantly ( $P < 0.05$ ) improved by probiotic bacteria dosage to aflatoxin treated group. These results indicated the healthy benefit and the positive effect of probiotic bacteria against toxicity induced by aflatoxins. This occurred as a result of decreased uptake of toxins caused by probiotic bacteria which lead to improve FCR and BWG (Solga, 2003).

The microbes present in probiotic would secrete amylase, protease and lipase, which would enhance the catalytic activities of the endogenous enzymes to liberate more energy from hydrolyzing the energy feed nutrients. Such higher quantity of liberated energy would help to improve BWG of the chicks fed probiotic added rations as compared to the chicks fed the rations containing no probiotic. Also, the microbes of probiotic in the intestinal tract of the inoculated birds may be secreting the amylolytic, cellulolytic, proteolytic and lipolytic enzymes (Biswas *et al.*, 1999; Bedford, 2001; Lázaro *et al.* 2003; Józefiak *et al.* 2004), which provide maximum help to enhance the digestibility of starch, protein and fat components in the sequential way and liberated maximum energy. Such energy would not only improve the overall vital activities in the birds, but also improve the BWG.

The Inclusions of desirable probiotic in the diet allows the rapid development of beneficial bacteria in the digestive tract of the host, improving

its performance (Edens, 2003). As a consequence, the improvement in the intestinal environment will increase the efficiency of digestion and nutrient absorption processes (Pelicano *et al.*, 2004).

**Table 4: Effect of aflatoxins contaminated diets and probiotic dosage on broiler chickens performance (at grower period 15-28 days of age) of different groups (Means  $\pm$ SD).**

Treatments	Item			
	Final body Weight (g)	Body weight gain (g)	Feed Consumption (g)	Feed conversion ratio
G1	1134 <sup>a</sup> $\pm$ 45	873 <sup>ab</sup> $\pm$ 57	1362 <sup>a</sup> $\pm$ 51	1.56 <sup>ab</sup> $\pm$ 0.05
G2	1042 <sup>b</sup> $\pm$ 57	785 <sup>c</sup> $\pm$ 56	1301 <sup>ab</sup> $\pm$ 97	1.66 <sup>a</sup> $\pm$ 0.08
G3	1038 <sup>b</sup> $\pm$ 17	793 <sup>c</sup> $\pm$ 32	1229 <sup>b</sup> $\pm$ 50	1.55 <sup>ab</sup> $\pm$ 0.06
G4	1160 <sup>a</sup> $\pm$ 18	898 <sup>a</sup> $\pm$ 23	1358 <sup>a</sup> $\pm$ 49	1.51 <sup>bc</sup> $\pm$ 0.05
G5	1162 <sup>a</sup> $\pm$ 24	899 <sup>a</sup> $\pm$ 23	1324 <sup>ab</sup> $\pm$ 57	1.47 <sup>c</sup> $\pm$ 0.05
G6	1111 <sup>a</sup> $\pm$ 53	852 <sup>ab</sup> $\pm$ 53	1319 <sup>ab</sup> $\pm$ 97	1.55 <sup>ab</sup> $\pm$ 0.09
G7	1113 <sup>a</sup> $\pm$ 69	854 <sup>ab</sup> $\pm$ 52	1356 <sup>a</sup> $\pm$ 46	1.59 <sup>ab</sup> $\pm$ 0.07
G8	1102 <sup>ab</sup> $\pm$ 51	845 <sup>b</sup> $\pm$ 24	1303 <sup>ab</sup> $\pm$ 89	1.54 <sup>ab</sup> $\pm$ 0.07
G9	1099 <sup>ab</sup> $\pm$ 63	851 <sup>ab</sup> $\pm$ 55	1319 <sup>ab</sup> $\pm$ 59	1.55 <sup>ab</sup> $\pm$ 0.08

a, b, c: Means within a column for each statistical analysis with common superscripts are significantly not different ( $P \geq 0.05$ ).

**Table 5: Effect of aflatoxins contaminated diets and probiotic dosage on broiler chickens performance (at finisher period 29-42 days of age) of different groups (Means  $\pm$ SD).**

Groups	Item			
	Final body Weight (g)	Body weight gain (g)	Feed consumption (g)	Feed conversion ratio
G1	2030 <sup>c</sup> $\pm$ 88	896 <sup>b</sup> $\pm$ 87	1702 <sup>b</sup> $\pm$ 71	1.90 $\pm$ 0.10
G2	2021 <sup>c</sup> $\pm$ 75	979 <sup>a</sup> $\pm$ 40	1829 <sup>a</sup> $\pm$ 63	1.87 $\pm$ 0.07
G3	1989 <sup>c</sup> $\pm$ 83	951 <sup>ab</sup> $\pm$ 38	1779 <sup>ab</sup> $\pm$ 83	1.87 $\pm$ 0.11
G4	2174 <sup>a</sup> $\pm$ 19	1014 <sup>a</sup> $\pm$ 26	1764 <sup>ab</sup> $\pm$ 67	1.74 $\pm$ 0.06
G5	2186 <sup>a</sup> $\pm$ 20	1024 <sup>a</sup> $\pm$ 29	1791 <sup>ab</sup> $\pm$ 55	1.75 $\pm$ 0.04
G6	2109 <sup>b</sup> $\pm$ 54	998 <sup>a</sup> $\pm$ 52	1796 <sup>ab</sup> $\pm$ 91	1.80 $\pm$ 0.11
G7	2108 <sup>b</sup> $\pm$ 28	995 <sup>a</sup> $\pm$ 40	1840 <sup>a</sup> $\pm$ 6	1.85 $\pm$ 0.11
G8	2079 <sup>b</sup> $\pm$ 55	976 <sup>ab</sup> $\pm$ 62	1837 <sup>a</sup> $\pm$ 35	1.88 $\pm$ 0.13
G9	2098 <sup>b</sup> $\pm$ 31	999 <sup>a</sup> $\pm$ 68	1820 <sup>a</sup> $\pm$ 24	1.82 $\pm$ 0.14

a, b, c: Means within a column for each statistical analysis with common superscripts are significantly not different ( $P \geq 0.05$ ).

**Table 6: Effect of aflatoxins contaminated diets and probiotic dosage on broiler chickens performance (overall period 0- 42 days of age) of different groups (Means  $\pm$ SD).**

Groups	Item			
	Final body Weight (g)	Body weight gain (g)	Feed consumption (g)	Feed conversion Ratio
G1	2030 <sup>cd</sup> $\pm$ 88	1990 <sup>bc</sup> $\pm$ 88	3336 <sup>ab</sup> $\pm$ 71	1.68 <sup>ab</sup> $\pm$ 0.05
G2	2021 <sup>ce</sup> $\pm$ 75	1981 <sup>bc</sup> $\pm$ 75	3394 <sup>ab</sup> $\pm$ 54	1.71 <sup>a</sup> $\pm$ 0.08
G3	1989 <sup>c</sup> $\pm$ 83	1949 <sup>c</sup> $\pm$ 83	3264 <sup>b</sup> $\pm$ 137	1.67 <sup>ab</sup> $\pm$ 0.06
G4	2174 <sup>a</sup> $\pm$ 19	2134 <sup>a</sup> $\pm$ 19	3387 <sup>ab</sup> $\pm$ 50	1.59 <sup>c</sup> $\pm$ 0.05
G5	2186 <sup>a</sup> $\pm$ 20	2146 <sup>a</sup> $\pm$ 20	3377 <sup>ab</sup> $\pm$ 73	1.57 <sup>c</sup> $\pm$ 0.05
G6	2109 <sup>b</sup> $\pm$ 54	2069 <sup>b</sup> $\pm$ 55	3386 <sup>ab</sup> $\pm$ 56	1.63 <sup>ab</sup> $\pm$ 0.09
G7	2108 <sup>b</sup> $\pm$ 28	2068 <sup>b</sup> $\pm$ 28	3464 <sup>a</sup> $\pm$ 104	1.68 <sup>ab</sup> $\pm$ 0.07
G8	2079 <sup>c</sup> $\pm$ 55	2039 <sup>b</sup> $\pm$ 55	3410 <sup>ab</sup> $\pm$ 97	1.67 <sup>ab</sup> $\pm$ 0.07
G9	2099 <sup>c</sup> $\pm$ 31	2058 <sup>b</sup> $\pm$ 27	3402 <sup>ab</sup> $\pm$ 55	1.65 <sup>ab</sup> $\pm$ 0.08

a, b, c, d: Means within a column for each statistical analysis with common superscripts are significantly not different ( $P \geq 0.05$ ).

Results in Table 7 revealed that positive controls (G2&G3) gave a significant increase in serum liver function enzymes, alanine aminotransferase (ALT) and aspartate aminotransferase (AST). Also showed significantly ( $P < 0.05$ ) higher urea and creatinine levels, as compared to healthy group fed the basal diet indicated the toxicity of aflatoxin on liver and kidney functions. These results are in coincide with those reported by Zohair (1996) in treated rats and those of Matri (2001) in Japanese quail birds received contaminated feed with aflatoxin and showing significantly higher ( $P < 0.05$ ) serum total cholesterol, creatinine and urea. On the other hand, the intakes of probiotic bacteria significantly ( $P < 0.05$ ) eliminated the elevation of ALT, AST, urea and creatinine level in aflatoxins treated broiler chickens. This result showed the detoxification activity of probiotic bacteria. The probiotic with AFB<sub>1</sub> bound to their surfaces likely to adhere to the intestinal wall and prolong exposure to dietary aflatoxin. Hence, specific probiotics may be potent and safe means to reduce absorption (Gratz *et al.*, 2006). In addition, the protective effects of probiotic bacteria against aflatoxin B<sub>1</sub> induced intestinal and systemic toxicity via binding and reducing its transport in different tested systems (Gratz, 2007). Results indicated also that the protective action of probiotic bacteria as a potential protective agent against aflatoxin toxicity as well as their beneficial health effects and may thereby offered an effective dietary approach to decrease the risk of occurrence of liver and kidney dysfunctions



**Table 7: Effect of aflatoxins contaminated diets and probiotic dosage on broiler chick serum parameters**

Groups	Item			
	AST,U/L	ALT,U/L	Uric acid mg/dl	Creatinine mg/dl
G1	69.33 <sup>b</sup> ±4.93	5.67 <sup>c</sup> ±0.58	3.54 <sup>b</sup> ±0.21	0.22±0.06
G2	89.67 <sup>ab</sup> ±11.06	8.67 <sup>a</sup> ±1.15	5.14 <sup>ab</sup> ±0.24	0.29±0.05
G3	98.67 <sup>a</sup> ±17.10	8.67 <sup>a</sup> ±1.53	5.49 <sup>a</sup> ±1.96	0.30±0.02
G4	83.00 <sup>ab</sup> ±14.93	6.67 <sup>bc</sup> ±0.58	4.65 <sup>ab</sup> ±0.44	.24±0.07
G5	71.67 <sup>b</sup> ±16.50	6.33 <sup>bc</sup> ±1.26	4.04 <sup>ab</sup> ±0.90	0.23±0.05
G6	85.67 <sup>ab</sup> ±11.37	7.00 <sup>b</sup> ±1.0	4.93 <sup>ab</sup> ±0.69	0.28±0.06
G7	84.67 <sup>ab</sup> ±9.29	6.67 <sup>bc</sup> ±0.58	4.70 <sup>ab</sup> ±0.59	0.24±0.06
G8	87.00 <sup>ab</sup> ±18.03	8.00 <sup>ab</sup> ±1.0	5.14 <sup>ab</sup> ±1.06	0.29±0.03
G9	85.00 <sup>ab</sup> ±8.66	7.67 <sup>ab</sup> ±1.15	5.06 <sup>ab</sup> ±0.96	0.28±0.06

a, b, c: Means within a column for each statistical analysis with common superscripts are significantly not different (P>770.05).

**Fig. 1: Residue of aflatoxin in thigh muscle (µg/kg wet tissue) of broiler of different tested groups.**

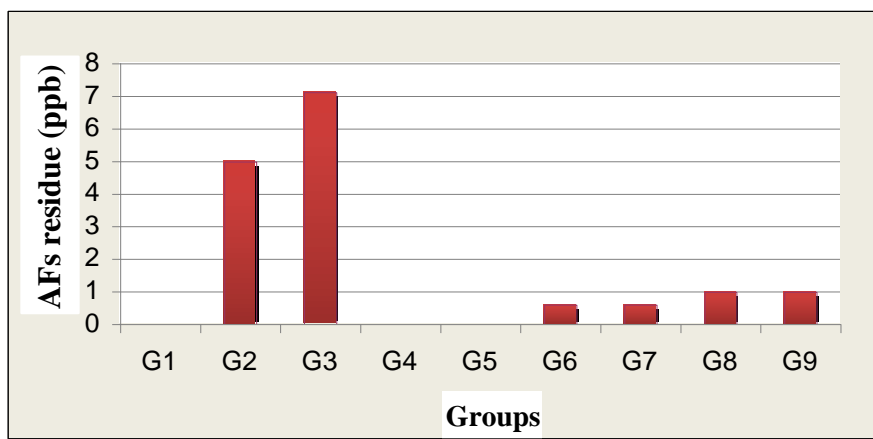


Fig. 1 shows the results of the aflatoxin residues analysis. Results showed that no AFs residue was detected in tissues of groups G1, G4 & G5. However, the levels of AFs residue in groups G2& G3 which fed on 0.5 and 1.0 mg AFs /Kg contaminated diet were 4.99& 7.12 ppb respectively.

Toxic residues of AFs in animal products were harmful to public health. In one-day Hubbard chicken, residues of AFs were 100, 250, 500 and 750ppb in liver, heart, breast muscle and kidney, respectively, as detected after 2 weeks of feeding the contaminated diet. AFs residue was decreased with increasing age of birds. In breast muscle, AFs residue was related to concentration of AFs in the diet (Teleb and Fakhry, 1988).

Aflatoxins tend to infiltrate most of the soft tissues and fat depots of the chicken (Leeson *et al.*, 1995). One day after the administration of a single

oral dose of C<sup>14</sup>-labelled AFB<sub>1</sub> to laying hens, the highest concentration of C<sup>14</sup> activity was detected in the liver, followed by muscle, pancreas, skin, adipose tissue, lungs and spleen (Sawhney *et al.*, 1973 a & b). In another study using C<sup>14</sup>-labelled aflatoxin, Harland and Cardeihac (1975) determined that the liver, kidney and bone marrow of chickens concentrated aflatoxins more readily than did brain, muscles or body fat.

**Histopathological examination:**

Microscopically, examination of chicken liver from G1 revealed no histopathological changes (Fig. 2). Meanwhile, liver of chicken from G2 showed accompanied with focal aggregations of inflammatory cells. Mild perivascular coagulative necrosis also occurred. Examined sections from G3 showed that hepatocytes existed vascular degradation thickening in the wall of arteries and veins with edema with distended hyperplastic bile ductules (Fig.9 ). Examined sections from G4 showed slight congestion of blood vessels.

Portal areas showed aggregation of macrophages and bile ductules hyperplasia (Fig.21). The G5 showed mild aggregation and macrophages and small lymphocytes were observed. Liver of chicken from G6 dispersion of hepatocytes due to edema and zonal necrosis with mild aggregations of inflammatory cells. Moreover, sections of liver from G7 revealed congested blood vessels accompanied with pronounced aggregation of inflammatory cells in portal area and marked activation of bile ductules (Fig.15). On the other hand, examined sections from G8 showed that blood sinusoids were dilated, perivascular cellular necrosis as well as periportal coagulative necrosis with heterophilic infiltration were found too (Fig.17) . Lee side thickening in the wall of bile ductules (Fig.18) . Examined sections from G9 which treated with high concentration of AFs and two doses of anaerobic caecal culture showed blood vessels with markedly congested central and portal coagulative necrosis. The inflammatory cells aggregations were more pronounced, more detectable bile ductules hyperplasia.

Although the liver is known to be the target organ of AFB<sub>1</sub>, respiratory exposure to AFB<sub>1</sub> contaminated dust has been linked with increased incidence of tumor in the respiratory tract of animals and humans. Biodegradation of AFB<sub>1</sub> by lung cells and by nasal mucosal epithelial cells, with subsequent formation of B<sub>1</sub>-DNA adducts has been reported (Daniels and Massey, 1992 and Tjalve *et al.*, 1992).

Kidneys of chicken from G1 revealed no histopathological changes (Fig. 3). Whereas, kidneys of chicken from G2 showed the majority of the renal tubular cells suffered from necrobiotic change (Fig.4), in addition to vacuolar degeneration. There was peripheral haemorrhage. Examined sections from G3 showed haemorrhage and congestion of renal blood vessels and granular degeneration of tubules epithelial cells. Examined sections from G4 showed congested blood vessels and haemorrhage were existed (Fig.22). The G5 showed no definite lesions. All renal blood vessels of Kidneys from G6 were congested (Fig. 13). The tubular epithelial cells suffered from necrobiotic changes. There was aggregation of inflammatory

(Fig.14). Sections of Kidney from G7 revealed pronounced congested blood vessels and hemorrhage. On the other hand, examined sections from G8 showed marked subcapsular and inter-tubular haemorrhage were observed with focal coagulative necrosis (Fig.19). Some renal tubules suffered from necrobiotic changes. Kidneys of chicken from G9 showed severely congested renal blood in addition to severe haemorrhage. The renal tubules suffered from coagulative necrosis with glomerular hypercellularity.

The results of histopathology obtained indicated the toxicity of aflatoxins in liver and kidney, these results walk in the same line with numerous animal studies which have shown that the liver is the main target organ and therefore the main symptoms of aflatoxin exposure in domestic laboratory animals are hepatic injuries (Robins and Richard, 1992 and IARC, 1993). In addition, Matri (2001) reported that severe histopathological changes were observed in the liver, kidney, heart, ovary and oviduct during aflatoxicosis. Also these results agree with Yener *et al*, (2009) who reported that the livers of the AF treated group were slightly pale, enlarged and grayish mottled in appearance. However addition of probiotic strains to aflatoxin treated rats showed improvement in the liver sections and showed no histopathological changes in kidneys as negative control. These results agree with Bekhatro (2008) who reported that liver of rat fed on *B. bifidum* 29521 showed no histopathological changes except minute vacuoles in the cytoplasm of some hepatocytes. In G2 heart, it showed intermyocardial haemorrhage and myomalacia. Spleen showed depletion of lymphocytes with proliferation of reticuloendothelial cells. Capillary sheathes were proliferation (Fig.5) with haemorrhage. Bursa reflected epithelial lining exhibited hyperplasia (Fig.6). Brain blood vessels were congested with haemorrhage mainly in the cerebellum (Fig.7). Spongiosis and neurons necrosis were observed (Fig.8). In G3 heart, myomalacia was observed with perivascular edema. Few heterophiles and reticular cells were detected in between muscle fibers (Fig.10). Spleen showed pronounced haemorrhage (Fig.11) and aggregation of reticulendothelial cells (macrophage) (Fig.12). Bursa epithelial hyperplasia was marked. Brain was affected with spongiosis and necrosis degeneration. In G4 heart, no definite lesions. Bursa with no definite lesions. Brain with no definite lesions. In G5 heart, no definite lesions. Spleen showed no definite lesions. Bursa with no definite lesions. Brain showed no definite lesions. In G6 heart, perivascular edema was detected. Spleen showed congested blood vessels and haemorrhage. Bursa with no definite lesions was observed. Brain showed swelling of neurons and edema was found. In G7 heart, edema was found in the myocardium. Bursa showed no definite lesions. Brain blood vessels were congested with perivascular edema, focal necrosis was observed. In G8 heart, affected with loss of muscular striation and heterophilic infiltration. Spleen showed haemorrhage and proliferation of capillary infiltration. Bursa showed no definite lesions. Brain with focal necrosed areas were detected (Fig.20). In G9 heart, the myocardial muscle fibers showed myocitis and myomalacia. Spleen: exhibited recognized lymphocytic depletion and marked haemorrhage. Bursa showed no definite lesions. Brain with focal enclosed area were found.

FIG

FIG

FIG

FIG

## CONCLUSION

From the obtained results and forgoing discussion, it could be concluded that the protective action of probiotic bacteria as a potential protective agent against aflatoxin toxicity as well as their beneficial health effects and may thereby offered an effective dietary approach to decrease the risk of occurrence of liver and kidney dysfunctions. Also, the results concluded that modulate the gut of hatched chicks in favor of beneficial commensally microorganisms for further improvement in growth rate based on good health status.

## REFERENCES

- A.O.A.C. (2006). Association of official analytical chemists of official methods of analysis ,18th ed., Washington. D.C.
- Bailery, J.S; L.C.Blankensheip;N.J.Stern;N.A.Cox and F. Mchan(1988). Effect of anticoccidial and antimiozobial feed additive on prevention of *salmonella* colonization of chicks treated with anaerobic a culture of chickens. *Faeces.Ad.Dis.*, 32:324-329.
- Bansal, G. R., V. P. Singh and N. Sachan (2011). Effect of probiotic supplementation on the performance of broilers. *Asia Journal of Animal Sciences*, 5 (4): 277-284.
- Bedford, A. (2001). Microbial interactions in response to exogenous enzyme utilization. In: *Enzymes in farm animal nutrition*. CABI Publish, 299–314.
- Bekhatro, M (2008). Studying the effect of probiotic bacteria in concerning the liver disorder. *Home Economic Nutrition and Food Sciences*, 194: 202.
- Biswas, T., L. Mandal and S. K. Sarker. (1999). Studies of enzymes supplementation and herbal preparation at different levels of energy on the performance of broilers. *J. Interacademic*, 3: 53-58.
- Chen, C., A. M. Pearson, T. H. Coleman, J. I. Gray, J. J. Pestka, and S. D. Aust.(1984). Tissue deposition and clearance of aflatoxins from broiler chicken fed a contaminated diet. *Food Chem. Toxicol*, 22:447–451.
- Dalvi, R. R. (1986). An overview of aflatoxicosis in poultry: its characteristics, prevention and reduction. *Vet. Res. Commun*, 10:429–443.
- Daniels, J. M. and T.E. Massey (1992). Modulation of AFB<sub>1</sub> biotransformation in rabbit pulmonary and hepatic microsomes." *Toxicology*, 74: 19-32.
- Davis, N.D.; V.L. Dioner, and D. W. El-Dridye (1966). Production of aflatoxins B<sub>1</sub> and G<sub>1</sub> by *Aspergillus flavus* in a semisynthetic medium. *Appl. Microbiol.*, 14: 378 – 380.
- Duncan, D.B. (1955). Multiple Range and Multiple F Tests. *Biometric*, 11: 1-42.
- Edens, F. (2003). An alternative for antibiotic use in poultry : Probiotics. *Brazilian J. Poult. Sci.*, 5(2):75-97.
- Feibelman, T.P.; P. J. Cotty; M. A. Doster and T. J. Michailides (1998). A morphologically distinct strain of *Aspergillus nomius*. *Mycologia*, 90: 618-623.



- Fritts, C., Kersey, J., Moti, M., Kroger, E., Yan, F., Si, J., Jiang, Q., Campos, M., Waldroup, A. and Waldroup, P. (2000). *Bacillus subtilis* C-3102 (Calsporin) improves live performance and microbiological status of broiler chickens. *J. Appl. Poult. Res.*, 9: 149-155.
- Gratz, S.; M., Täubel; R.O., Juvonen; M., Veluksela; P.C., Turner; H., H. Mykkänen and H., EL-Nezami (2006). Lactobacillus Ramnosus Strain GG modulates Intestinal Absorption Of Aflatoxin B<sub>1</sub> And Its Fecal Excretion And Toxicity In Rats. *Appl. Environ microbiol.* 1128, AEM 01348-06.
- Gratz, S.; Q.K., Wu; H., EL-Nezami; R.O., Juvonen; H. Mykkänen and P.C., Turner (2007). Lactobacillus Ramnosus strain GG reduces aflatoxin B<sub>1</sub> transport metabolism and toxicity in Caco-2 cells. School of Public Health and Clinical Nutrition, Clinical Nutrition and Food and Health Research Center, University of Kuopio.
- Gratz; Mykkanen, H. and El nezami, H. (2005). Aflatoxins B<sub>1</sub> binding by a mixture of lactobacillus and propiobacterium: In vitro versus ex vivo. *Journal of food protection* (11); 2470-2474.
- Harland, E. C. and P. T. Cardeilhac (1975). Excretion of carbon-14-labeled aflatoxin B<sub>1</sub> via bile, urine and intestinal contents of the chicken. *Am. J. Vet. Res.*, 36: 909-912.
- IARC International Agency for Research on Cancer (1993). IARC monograph on the evaluation of carcinogenic risks to humans: Some naturally occurring substances food items and constituents, heterocyclic aromatic amines and mycotoxins. *IARC Monographs*, 56: 245.
- Józefiak, A., M.F. Rutkowski and D. Boros. (2004). The effect of dietary fiber fractions from different cereals and microbial enzymes supplementation on performance, ileal viscosity and short-chain fatty acids concentration in caeca of broiler chickens. *Anim. Feed Sci.* 13: 487–496.
- Lázaro, M., P.M. Garcia and G.G. Mateos. (2003). Influence of enzymes on performance and digestive parameters of broilers fed rye-based diets. *Poult. Sci.*, 82: 132–140.
- Leeson, S.; G. J. Diaz, and J. D. Summers (1995). *Poultry metabolic disorders and mycotoxins*. Pp. 249-298, University Books, Guelph, Ontario, Canada.
- Matri, A. (2001). Identification of fungal contamination and determination of mycotoxigenic molds by micellar electrokinetic capillary chromatography in smoked paprika. *Journal of Food Protection*, 68: 815–822.
- NMKL, Nordic Committee on Food Analysis (1999): *Quality Assurance Guidelines for Microbiological Laboratories*. Report No 98 3rd edition.
- National Research Council, NRC (1994). *Nutrient Requirements of Poultry*. 9<sup>th</sup> rev.ed. National Academy Press, Washington, DC.
- Parlat, S. S.; A. O., Yildiz; and H., Oguz (1999). Effect of Clinoptilolite on performance of Japanese Quail (*Coturnix coturnix japonica*) during experimental aflatoxicosis. *Br. Poult. Sci.*, 40: 495-500.
- Pearse, A.G.W. (1968): *Histochemistry theoretical and applied*. Vol.1, 3<sup>rd</sup> Ed. Vol 1 Churchill, Livingstone, Edinburgh, London and New York.

- Pelicano, E., Souza, P., Souza, H. Leonel, F., Zeola, N. and Boiago, M. (2004). Productive traits of broiler chickens fed diets containing different growth promoters. *Brazilian J. Poult. Sci.*, 6(3):177-182.
- Rahman, A. U.; S. Khan; D. Khan; M. Hussain; S. Ahmed; S. M. Sohail; I. Ahmed; I. U. Haq and Z. Shah (2009): Use of probiotics in broiler feed at starter phase. *Sarhad J. Agric.*, 25 (3): 469-474.
- Robins, J.F. and J.L., Richard (1992). Aflatoxins in animal and human health. *Rev. Environ. Contam. Toxicol.*, 127: 6994.
- Roos, A. H.; H. J. Van der Kamp; and E. C. Marley (1997). Comparison of immunoaffinity columns with Florisil/ C18 columns for the determination of aflatoxins in animal feed and maize. *Mycotoxin Research*, 13: 1-10.
- SAS, Institute.(1990).SAS@User'sGuide, Statistics.Version6th ed.SAS Institute.NC.USA.
- Sawhney, D. S.; D. V. Vadehra, and R. C. Baker (1973b). The metabolism of <sup>14</sup>C aflatoxins in laying hens. *Poult. Sci.*, 52: 1302-1309.
- Sawhney, D. S.; D.V. Vadehra, and R. C. Baker (1973a). Aflatoxicosis in the laying Japanese quail. *Poult. Sci.*, 52: 485-493.
- Solga, S.F.( 2003): Probiotics can treat hepatic encephalopathy. *Med Hypotheses*, 61:307-313.
- Teleb, H. M. and F. M. Fakhry (1988). AF B<sub>1</sub> residue in broiler and its effect on fat metabolism. *Journal of Veterinary Medicine, Giza, Egypt*, 36: 135-145.
- Tjalve, H.; P. Larson; C. Anderson, and L. Buck (1992). Bioactivation of AFB1 in the bovine olfactory mucosa: DNA binding, mutagenicity and induction of sister chromatide exchanges. *Carcinogenesis*, 13: 1345-1350.
- Tránsito, L. S.; J. D.R. García; J. L. A. Román; E. M. Martínez and A. M. Albores (2011). Effect of citric acid supplemented diets on aflatoxin degradation, growth performance and serum parameters in broiler chickens. *Arch. Med. Vet.*, 43: 215-222.
- Weidenbörner, M. (2007). *Mycotoxins in Feedstuffs*. Springer-Verlag, New York Inc,
- Wolzak, A., A. M. Pearson, T. H. Coleman, J. J. Pestka, J. I. Gray, and C. Chen. (1986): Aflatoxin carryover and clearance from tissues of laying hens. *Food Chem. Toxicol.*, 24:37-41.
- Yener, Z; I., Celik; F., Ihan and R., Bal (2009). Effects of *Urtica dioica* L. seed on lipid peroxidation, antioxidants and liver pathology in aflatoxin-induced injury in rats. *Food and Chemical Toxicology*, 47: 418-424.
- Zohair, Azza (1996). Destruction of aflatoxin in peanut and peanut products, PhD, Ain Shams University. Cairo, Egypt.

### تأثير بروبيوتيك بكتيري على سمية الأفلاتوكسين في كتاكيت التسمين:

أداء النمو، قياسات السيرم و التغيرات النسيجية

طارق محمد العفيفي<sup>١</sup>، أمل عبد الغزيز ابو حجر<sup>١</sup>، اسيا محمد الصاوي<sup>٢</sup>،

احمد فريد عبد السلام<sup>١</sup> و خالد مصطفى المليجي<sup>١</sup>

١- المركز الإقليمي للأغذية والأعلاف - مركز البحوث الزراعية - الجيزة - مصر.

٢- معهد صحة الحيوان - مركز البحوث الزراعية- الدقى - مصر.

أجريت هذه الدراسة لتقييم القدرة على إزالة الأفلاتوكسين بواسطة بروبيوتيك بكتيري. استخدم في هذه التجربة ٢٧٠ كتكوت تسمين روس عمر يوم<sup>١</sup>، تم تقسيمها عشوائياً إلى ٩ معاملات . المعاملة الأولى كمنترول، ٢،٣ تم تلويث عليقة الكمنترول صناعياً بواسطة ٠,٥، ١، ٥ مجم أفلاتوكسين على التوالي ٤،٥، تتناول العليقة الكمنترول ويتم تجريعها مرة أو مرتين بروبيوتيك بكتيري على التوالي، (٦،٧) على الترتيب الجرعة المنخفضة من الأفلاتوكسين (٥. مجم) وتجريعها مرة أو مرتين من بروبيوتيك بكتيري (٩،٨) الجرعة العالية من الأفلاتوكسين (١ مجم) وتجريعها مرة أو مرتين من بروبيوتيك بكتيري على التوالي . القياسات التي تم تقديرها هي عائد وزن الجسم ، العليقة المستهلكة ، وكفاءة تحويل الغذاء . التأثير السام للأفلاتوكسين في المجموعات التي تتناول أفلاتوكسين أظهرت نقصاً معنوياً في عائد وزن الجسم ، والعليقة المستهلكة وسوء معامل التحويل الغذائي مقارنة بالمجموعة التي تتناول الكمنترول . النقص في عائد وزن الجسم والعليقة المستهلكة وكفاءة تحويل الغذاء تحسن بواسطة إضافة بروبيوتيك بكتيري مع الأفلاتوكسين من ناحية أخرى ، الأفلاتوكسين تؤدي إلى زيادة معنوية في انزيمات وظائف الكبد ، (انزيم الناقل للحامض الأميين ألانين والانزيم الناقل للحامض الأميين أسبرجين واليوربا والكرياتين) . النتائج أظهرت التأثير الوقائي بروبيوتيك بكتيري الفعال ضد سمية الأفلاتوكسين بالإضافة إلى التأثيرات الصحية الإيجابية وتقليل المخاطر على وظائف الكبد والكلية ويقلل التأثير السرطاني ربما يكون لقدرتها على ربط الأفلاتوكسين وتقليل المتناول من الأفلاتوكسين ويعمل على حماية كل الاعشية و عدم تحطم DNA .

### قام بتحكيم البحث

كلية الزراعة - جامعة المنصورة  
المركز القومي للبحوث

أ.د / عبد الحميد محمد عبد الحميد  
أ.د / ياسر احمد فتحى حموده